(47)

PATHOLOGICAL REPORTS

MONTREAL

GENERAL HOSPITAL.

NO. III.

For I & II see Order, nos. 35-36-7.

REFERENCE INDEX OF POST-MORTEMS

FROM

1883 TO 1895.

COMPILED BY

WYATT JOHNSTON, D. D. MACTAGGART

AND

F. L. JOHNSTON.

GAZETTE PRINTING CO., MONTREAL.

In trying to obtain an idea of the associations under which a particular disease or lesion has been met with in the experience of others, one becomes impressed with the difficulty of obtaining statistical information. In the casuistic literature only those aspects of the cases are treated fully which attract attention at the time. In the matter of pathological records it is difficult to find a sufficient number of cases showing all the chief complications of the principal disease.

The increased attention now being paid to the indexing of pathological reports and the publishing brief abstracts of the chief pathological changes found in the routine autopsy records promises to yield a mine of valuable information. The manner in which this can best be recorded is not an easy matter to decide, but, no abstract or synopsis of an autopsy is as compact and convenient as the simple publication of the anatomical diagnosis in all the cases coming to autopsy during the year as was done for the first time by Drs. Adami and Martin in the case of the Royal Victoria Hospital, Montreal.

In order to facilitate reference we have added a special index in which the morbid conditions are placed under the particular organ or system to which they belong and recorded by the reference number. We have to thank Dr. Martin for permitting us to consult the very full (unpublished) nosological list compiled by him.

It was thought best not to depend upon an alphabetical arrangement but to classify as far as possible in a nosological manner. The perfect type of such a classification would be one where the conditions were "double-indexed" and recorded, first under their relation to general pathology and then under the organ affected. In classifying the diseases of the different organs the natural order to follow is that used by most text-books on pathology, viz. : 1. anomalies ; 2. circulatory disturbances ; 3. inflammations and infections (it becomes harder and harder for us to separate the two in view of recent investigations) ; 4. progressive changes ; 5. retrogressive changes, lastly, 6. injuries and foreign bodies.

A complete system of double entry was found in practice to make the index too bulky and we have only duplicated in certain special instances. In deciding when double indexing was necessary we were largely guided by whether the clinical importance of the particular lesion in question was much influenced by the organ affected. Thus amyloid degeneration being

capable of very wide distribution, as a rule, without much clinical interest attaching to its particular location, was not double-indexed; whereas tumours, suppurations and any other conditions in which widely different clinical results depend upon the situation of the lesions, were entered both under the general and special pathological headings. In the case of the lesions which only affect one kind of tissue, e.g. fractures, all that appeared necessary was to enter them in one place, under bones. Owing to the diversity and clinical importance of the localisation in tuberculous lesions they were double indexed. Where the index is not duplicated a cross reference is given.

The fact that the autopsies were performed by a number of different persons and that during the period covered there were no less then 15 complete changes of management of the laboratory, makes it difficult to classify uniformly. Where doubt exists as to the opinion held we have employed the phraseology used by the person who made the autopsy. In the anatomical diagnoses the principal disease is given first rather than the immediate cause of death.

Common conditions of little clinical significance are mentioned as a rule when they had a special interest in that particular case or were strikingly well marked. As to how far these records have an exact statistical value as showing the relative frequency of different morbid conditions, this is in our opinion much less than in the case of a small series covering a short time only, where either a positive or negative result is recorded in each case. The observations of a dozen men extending over as many years are bound to be diverse and unequal as to the frequency with which particular lesions are looked for. When however, persistent frequency is noted of any particular condition there is all the more reason to rely on the result of the observations. We notice that the proportion which pulmonary tuberculosis bears to the total deaths from all causes is practically the same as that determined by mortality statistics for this city and province. The frequency with which interstitial changes are noted in the kidneys also accords with the recent literature of the subject. The cases may be as a whole taken as typical of the ordinary run of hospital cases though as the autopsy is not a matter of hospital routine but requires the consent of the relatives there is a relatively large proportion of rare and exceptional cases, because in these more trouble is naturally taken to obtain this consent.

One thing noticed was a decided falling off in the percentage of cases of amyloid degeneration during the last 10 years, doubtless owing to improved methods of treating suppurative conditions and to the better facilities for making early diagnosis and averting the graver forms of many chronic diseases.

The rarity of certain diseases, notably malaria, is peculiar to the locality. In regard to rare conditions, however, these come in a very irregular manner. Thus trichinosis was only met with in two cases during the 20 years covered by the hospital post-mortem records, and both of these occurred within a few months.

I may instance a remark of Dr. Osler in his text-book to the effect that in his Montreal cases internal hæmorrhagic pachymeningitis had been absent while it was of frequent occurrence in the service at the Blockley Alms House in Philadelphia. Personally I have found this condition to be of frequent occurrence in Montreal, but only in autopsies in coroners' cases, this special class of material not having been available in Dr. Osler's time.

It is to be regretted that the means at our disposal do not permit of the publication at present of a full analysis of the pathological material in the autopsy records. It is hoped to do so later in a series of shorter reprinted articles. In addition to the present series of 934 post-mortems, we also hope shortly to index a series of 700 post-mortems, which were made by Dr. Osler during the period from 1876, when the pathological department of the hospital was first established, to 1882, as well as a series of 400 medico-legal autopsies made since 1893 by myself.

It must be mentioned that the series now indexed is composed of autopsies made before any properly equipped pathological laboratory existed in connection with the hospital. In consequence the bacteriological and microscopical study is much more scanty than would otherwise have been the case. At present, thanks to a better laboratory and a larger staff we are able to follow the current methods of the modern laboratories, in which a microscopical and bacteriological examination of all the principal organs is made in every case as a matter of routine. On comparing the present and past pathological work of the General Hospital, what impressess me most is the high standard of work done by my predecessors, Drs. Osler and Adami, under very unfavourable circumstances as to laboratory equipment and assistance.

I have great pleasure in recording my appreciation of the substantial encouragement which the Hospital Committee of Management have given to the pathological laboratory at a time when very heavy calls were being made upon the Hospital funds.

We hope in the future to be able to keep our pathological indexes published up to date and would be glad to see an inter-laboratory arrangement whereby copies of autopsy reports could be furnished to persons interested in studying any special class of cases and willing to defray the expense of the clerical work involved.

MONTREAL, August, 1897. W. JOHNSTON.

CONTENTS.

PAGE.

General Index, 1883 1
1884 8
1885 11
1886 17
1887 25
1888 33
1889 40
1890 47
1891 54
1892 56
1893 59
1894 66
1895 70
Table showing number of autopsies in each year 82

SPECIAL INDEX—

GENERAL PATHOLOGY.

Anomalies 83
Inflammations, Infections and General Diseases 83
Tumours 86
Degenerations 87
Injuries, Operations, Violent Death, Artifacts 88

SPECIAL PATHOLOGY—

CIRCULATORY SYSTEM.

Vessels, Blood 90
Heart 91

LYMPHATIC SYSTEM—

Spleen 94
Lymphatics 93
Thymus, Adrenals, Bone-marrow 94

RESPIRATORY SYSTEM—

Pleura 95
Lungs 95
Larynx, Upper Air-passages, Pharynx 97

DIGESTIVE SYSTEM—

Mouth 98
Stomach and Oesophagus 98
Intestines 98
Appendix 99
Liver 100
Gall Bladder 101
Pancreas 102
Peritoneum, Mesentery 101

URINARY SYSTEM—

Kidney 102
Bladder, Urethra 103

PAGE.

MALE GENITAL SYSTEM—
Penis 104
Prostate 104
Testes 104
FEMALE GENITAL SYSTEM—
Vulva 104
Vagina 104
Uterus 105
Ovaries 105
Fallopian Tubes 105
Mamma 105
Fœtus 105
CUTANEOUS SYSTEM—
Skin and Appendages 108
NERVOUS SYSTEM—
Brain and Membranes 106
Spinal Cord 107
Nerves 107
LOCOMOTOR SYSTEM—
Bones 107
Joints 108
Muscles 108
Fascia 108

GENERAL AND SPECIAL INDEX OF POST MORTEMS PERFORMED AT THE MONTREAL GENERAL HOSPITAL DURING THE PERIOD FROM 1883 TO 1895.

AUTOPSIES MADE BY: WM. OSLER, J. G. ADAMI, F. G. FINLEY, R. J. B. HOWARD, W. H. JAMIESON, WYATT JOHNSTON, H. A. LAFLEUR, C. F. MARTIN, W. R. SUTHERLAND AND E. P. WILLIAMS.

INDEX PREPARED BY WYATT JOHNSTON, D. D MACTAGGART AND W. F. L. JOHNSTON.

GENERAL INDEX.

1883.

701 (Osler)—Female, 40. Jan. 10, 1883.

CHRONIC ULCERATIVE PHTHISIS. Cavity in right lung; fibroid and fatty liver, with Liebermeister's furrows.

702 (Osler)—Female, 40. Jan. 10, 1883.

PURULENT BRONCHITIS. Cystic bronchocele; cyst at apex of left pleura, continuous with bronchocele. Sub-peritoneal fibroid of uterus.

703 (Osler)—Female, 57. Jan. 14, 1883.

FRACTURE OF BASE OF SKULL. Slight atheroma of mitral and aortic valves; chronic adhesive pleurisy; calcareous plate in right pleura; cartilaginous looking fibroid areas of left pleura; meningeal hæmorrhage and multiple ecchymoses of pia; hæmorrhage of pons; fatty liver; granular kidneys, with cysts.

704 (Osler)—Male, 25, private case. Jan. 24, 1883.

SPLENIC MYELOGENOUS LEUCHÆMIA. Hyperplasia of spleen, 7½ lbs.; hyperplasia of mesenteric and retro-peritoneal glands, and bone marrow; dilatation (and thrombosis?) of portal and mesenteric veins; catharrhal enterocolitis, hyperplasia of solitary follicles to double normal size; leuchæmic liver and kidneys; dilatation and fatty degeneration of heart; pyoid marrow; ulcerative cystitis.

705 (Osler)—Child, 5 months, private case. Jan. 27, 1883.

ŒDEMA OF GLOTTIS. Wrinkled condition of aryepiglottic folds; true and false vocal cords covered with catharral exudation; spleen large.

706 (Osler)—Female, 26. Jan, 27, 1883.

PHTHISIS. PYOPNEUNOTHORAX. Perforation near anterior border of upper lobe of left lung; empyema; extensive tuberculosis with cavities; mitral and aortic valves thickened; a few spots of atheroma in aorta at lower part of arch; uterine mucosa congested; varicosity of ovarian veins.

707 (Osler)—Female, 4. Feb. 2, 1883.

DIPHTHERIA. Tracheotomy; diphtheritic membrane over epiglottis, larynx and trachea, forming a complete cast above tracheotomy incision, below orifice mucosa deeply congested; left lung collapsed, commening pneumonia in right lung.

708 (Osler)—Male, 26. Feb. 6, 1883.

ULCERATIVE ENDOCARDITIS. Fusion of aortic segments. Thick, fleshy vegetations on valve; perforation, 3 mm from edge of left half of fused valve; vegetations extend below base of single segment towards mitral valve. Hypertrophy and dilatation of heart. Lungs hyperæmic; bases oedematons. Kidneys large (cyanotic induration); show old and recent infarcts, and numerous hæmorrhagic infarcts in cortices. Spleen acute enlargement; intestines show infarctions beneath mucosa; fluke deformity of left liver lobe; catarrhal gastritis and ecchymosis. Acute hæmorrhagic embolic lepto-meningitis.

709 (Osler)—Female, 16. Feb. 18th, 1883.

PHTHISIS. Numerous cavities; fibroid change in both lungs; acute tuberculous pleuritis with subpleural hæmorrhage; miliary tubercles of spleen; tuberculous ulceration of intestine, most marked in jejunum and cæcum; tuberculosis of vagina. Liver fatty.

710 (Osler)—Male, 23. Feb. 19th, 1883.

PULMONARY PHTHISIS. Emphysema; rupture of aneurism of pulmonary artery; mesenteric glands enlarged.

711 (Osler)—Male, 6. Feb. 20, 1883.

DIPHTHERIA of pharynx and posterior nares; enlargement of glands of neck.

712 (Osler)—Private case. March 3, 1883.

FIBRO MYOMA OF UTERUS.

713 (Osler)—Male, 27. March 4, 1883.

ACUTE GENERAL MILIARY TUBERCULOSIS. Lungs stuffed with miliary tubercles, caseous nodules at apices; hyperplasia of spleen (3 times, normal size); a few miliary tubercles in calices of kidneys.

714 (Osler)—Male, 12. March 10, 1883.

CARIES OF CERVICAL VERLEBRÆ. Tuberculosis; Cavity in lung, apex (size of walnut); amyloid spleen; nutmeg liver.

715 (Osler)—Female, 5. March 9, 1883.

DIPHTHERIA. Membranous laryngitis and tracheitis; atelectasis of left lung, inflation of right lung.

716 (Osler)—Male, 19. March 8, 1883.

CHRONIC PARENCHYMATOUS NEPHRITIS. Anasarca; chylous ascites and hydrothorax; (3 to 4 pints milky fluid in peritoneum); mesenteric and retro-peritoneal lymph glands enlarged; thoracic duct normal.

717 (Osler)—Male, 32. March 15, 1883.

SUPPURATIVE ARTHRITIS OF HIP AND KNEE JOINTS. Nutmeg liver; pyæmia; icterus; amyloid kidney.

718 (Osler)—Child, 5 months. Private case.

ROUND CELLED SARCOMA OF KIDNEY. Sarcomatous thrombosis with obliteration of right iliac artery and vein and vena cava.

719 (Osler)—Female, 53. Private case. March 23, 1883.

CANCER OF CERVIX UTERI. Left hydronephrosis; nutmeg liver; Cancerous infiltration of rectum and bladder.

720 (Osler)—Female, 65. March 26, 1883.

GLIOSARCOMA OF BRAIN in region of 3rd ventricle and infundibulum; Brown athrophy of heart; adhesive peritonitis and perihepatitis. Dilatation of bile-ducts.

721 (Osler)—Male, 76. March 26, 1883.

FRACTURE OF BASE OF SKULL (Notes not entered).

722 (Osler)—Male, 80.

SOFTENING OF BRAIN. Multiple atheroma of arteries: miliary aneurisms; atheroma of coronaries; hypertrophy of left verticle; atheroma of heart valves. Slight chronic interstitial myocarditis; emphysema of margins of lungs; œdema of lungs; mucopurulent bronchitis; thickening of capsule of spleen; extreme senile athrophy of kidneys with cysts.

723 (Osler)—Private Case, Male. March 27, 1883.

CHRONIC INTERSTITIAL NEPHRITIS. Hyperæmia and œdema of lungs; fatty liver; hypertrophy of middle lobe of prostate; diverticulum of bladder; œdema of pia mater. Uræmia (?)

724 (Osler)—Female, 28. March 28, 1883.

PHTHISIS; ULCERATIVE ENDOCARDITIS.

725 (Osler)—Private case, 73. March 22nd, 1883.

ANEURISM OF AORTA, ascending arch. Rupture into pericardium.

726 (Osler) Male, 55. March 29, 1883.

PHTHISIS. Emphysema of anterior margins of lungs; large cavity in left lung.

727 (Osler)—Female, 39. April 7, 1883.

CHRONIC INTERSTITIAL NEPHRITIS. Pregnancy. Uræmia. Congestion and cloudy swelling of kidneys; hyperaemia and oedema of lungs; punctate ecchymosis of liver. Hæmorrhage of left corpus striatum and left ventricle; gestation nearly at term; fœtus in utero.

728 (Osler)—Male, 65. April 10, 1883.

CEREBRAL HÆMORRHAGE.

729 (Osler)—Female, 50. April 11, 1883.

ACUTE BRONCHO-PNEUMONIA. Atheroma of aortic and mitral valves; cloudy swelling of kidney; slight fatty liver; atheroma of aorta; chronic bronchitis and emphysema in both lungs.

730 (Osler)—Male, 48. April 12, 1883.

CHRONIC TUBERCULOUS PERITONITIS WITH EFFUSION. PERFORATION OF TUBERCULOUS ULCER OF INTESTINE. Tuberculous entero-colitis; extensive tuberculosis with cavities in both lungs. Tubercles in capsule of spleen. Tuberculous perihepatitis.

731 (Osler)—Male, 28. April 14, 1883.

CHRONIC ULCERATIVE PHTHISIS of both lungs. Fluke shape deformity of left lobe of liver; fatty liver; one small tuberculous ulcer in ileum.

732 (Osler)—Male, 63. April 11, 1883.

CHRONIC INTERSTITIAL NEPHRITIS. Dilatation and fatty degeneration of heart; emphysema; adhesions at apices.

733 (Osler)—Male, 8. April 15, 1883.

DIPHTHERIA. Apical tuberculosis of lung (both); cloudy swelling of kidneys; pseudo-membranous pharyngitis.

734 (Osler)—Male, 53. April 15, 1883.

CHRONIC ULCERATIVE PHTHISIS of both lungs; slight insterstitial nephritis; several small tuberculous; ulcers in ileum and colon.

735 (Osler)—Private.

UMBILICAL HERINA.

736 (Osler)—Not entered.

737 (Osler)—Female, 52. April 24, 1883.

COLLOID CANCER OF PANCREAS. Secondary in lung; no cancer in liver.

738 (Osler)—Male, 35. May 1, 1883.

PHTHISIS. Cavity of left upper lobe; acute pleurisy over right lower lobe; tuberculous enteritis; Chyle extravasations in mesentery; enlarged lymph glands.

739 (Osler)—Female, 60. May 9, 1883.

PERNICIOUS ANÆMIA. Brown atrophy of heart; chronic interstitial nephritis; stomach mucosa, pale thin and tough; liver elongated left lobe; aorta atheromatous; iliacs rigid; submucous fibromyoma uteri.

740 (Osler)—Male, 8. May 9, 1883.

ACUTE NEPHRITIS FOLLOWING SCARLATINA. Anasarca; ascites; hydrothorax; atelectasis.

741 (Osler)—Female, 18. May 14, 1883.

CHRONIC ULCERATIVE PHTHISIS of both lungs. Tuberculous pleurisy adhesive perihepatitis; eight to ten tuberculous ulcers in ileum; a single ulcer in colon; adhesive pelvic peritonitis; hydrosalpynx.

742 (Osler)—Male, 38. May 30, 1883.

ACUTE SPINAL MYELITIS.

743 (Osler)—Male, 60. May 29, 1883.

HYPERTROPHY AND DILATATION OF HEART on both sides; Chronic mitral endocarditis with stenosis; presistent foramen ovale; emphysema; chronic interstitial nephritis; cirrhosis of liver; ascites; hydrothorax.

744 (Osler)—Female, 23. June 3rd, 1883.

GENERAL MILIARY TUBERCULOSIS. Adhesive pericarditis; miliary tuberculosis of lungs and kidneys; extensive adhesive pleurisy; caseous bronchial glands.

745 (Osler)—Female, 85. June 11, 1883.

CANCER OF STOMACH. Secondary cancer (?) of retroperitoneal glands; fibroid change of myocardium; brown atrophy of heart; atheroma of aorta; pigmentation and pseudo tubercles of pleura; emphysema; chronic bronchitis; fibroid and fatty liver; thrombosis of left renal vein; papillomatous cyst of left ovary.

746 (Osler)—Male, 6. July 20, 1883.

ACUTE TUBERCULOUS MENINGITIS. (Notes not entered).

747 (Osler)—Male, 24. July 16, 1883.

PHTHISIS. Cavities in both lungs; dilatation of right side of heart; spleen enlarged, with two supplamentary spleens; amyloid liver; granular kidney with amyloid. Enlarged gland in portal fissure.

748 (Osler)—Male, 32. June 16, 1883.

PERNICIOUS ANÆMIA. Lemon yellow tint of skin; heart hypertrophied; (410 gm.) and dilated with fatty degeneration; œdema of lungs; spleen enlarged and adherent to diphragm; kidneys anæmic enlarged (200 gm.) capsule adherent; liver yellowish-brown; marrow of femur red; mesenteri glands deep red.

749 (Osler)—Male, 52. August 19, 1883.

TYPHOID FEVER. Typhoid ulceration of Peyer's patches; enlargement of mesenteric glands; enlargement of spleen; pneumonia of right lung, congestion and œdema at bases of both lungs.

750 (Osler)—Male. Aug. 1, 1883.

TYPHOID ULCERATION OF INTESTINES. Swelling of mesenteric glands; pneumonia at bases of lungs; cloudy swelling of kidneys and liver; ecchymosis over surface of liver; gritty particles in gall bladder.

751. (Osler)—Female, 4. August 4, 1883.

ŒDEMA OF GLOTTIS. Tracheotomy; abnormal degree of mobility of cervical vertebræ.

752. (Osler)—Male, 39. August 2, 1883.

CONTUSION OF HEAD; HÆMORRAGE INTO RIGHT EXTERNAL CAPSULE. Red softening of brain. Concussion ecchymoses on island of Reil; commencing meningitis (?) Hyperæmia of lungs.

753 (Osler)—Male, 64. August 3, 1883.

ACUTE PLEURISY. Congestion of lungs; venesection; fatty and parenchymatous degeneration of heart; slightly granular kidneys; atheroma of coronary arteries; fatty and cirrhotic liver.

754 (Osler)—Male, 39. August 12, 1883.

DOUBLE TUBERCULOUS PYELITIS. Acute miliary tuberculosis of both lungs and pleura; at both apices small caseous areas; tuberculosis of bladder; fistula of urethra; miliary tubercules in liver; hyperplasia and tuberclosis of spleen.

755 (Osler)—Male, 42. August 9, 1883.

HYPERTROPHY AND DILATATION OF HEART. General arterio-sclerosis (venesection).

756 (Johnston)—Male, 36. August 13, 1883.

FRACTURE OF BASE OF SKULL. Laceration of scalp; œdema of lungs; Necrosing cystitis; menengeal hæmorrhage.

757 (Johnston)—Male, 19. (First Ambulance Case, M. G. H.) August 13, 1883.

RUPTURE OF LEFT KIDNEY AND SPLEEN. Fracture of ribs in railway accident.

758 (Johnston)—Male, 39. August 13, 1883.

TYPHOID FEVER; PERFORATION AND PERITONITIS. Typhoid ulceration of intestines; hyperplesia of spleen and mesenteric glands; cloudy swelling of kidneys.

759 (Osler)—Private case. August 17, 1883.

PRIMARY CANCER OF LIVER. Secondary in lungs.

760 (Osler)—Male, 21. August 17, 1883.

CHRONIC SUPPURATIVE CALCULOUS PYELITIS OF BOTH KIDNEYS. Amyloid kidney, liver and spleen. Ulcerative colitis.

761 September 25, 1883.

CHRONIC ENDOCARDITIS with hypertrophy and dilatation. Chronic bronchitis; hyperplesia of spleen; arteriosclerosis; Liebermeister's furrows of liver; catarrhal gastritis.

762 (Osler)—Male, 29. September 23, 1883.

EPITHELIOMA OF PENIS. Secondary of inguinal glands; infarction (cancerous (?)) and abscess at base of right lung.

763 (Osler)—Female, 43. October 1, 1883.

TYPHOID FEVER; DIPHTHERIA OF TRACHEA AND BRONCHI. Slight chronic interstitial nephritis; hyperplasia of spleen; typhoid ulceration of intestines.

764 (Osler)—Male, 23, October 3, 1883.

FRACTURE OF SKULL. Intermeningeal hæmorrhage and concussion ecchymoses of brain; collapse and hyperæmia with œdema of lungs.

765 (Osler)—Male. October, 26, 1883.

ANEURYSM OF ABDOMINAL AORTA. Rupture into peritoneum.

766. (Osler)—Male, 35. October 9, 1883

PHTHISIS. Tuberculous peritonitis with effusion; cavity in left lung; gray hepatization of right lung; hyperplasia of spleen; catarrhal gastritis; cirrhosis of liver.

767 (Osler)—Female. October 14, 1883.

RENAL CIRRHOSIS. Hypertrophy of left ventricle; hyperæmia and œdema of lungs; cheesy and calcified nodule at apex; kidneys 36 grm. each; extreme chronic insterstial nephritis with arterio-sclerosis; dysenteric ulceration of intestine; pyosalpynx; cyst in right broad ligament; atheroma of aorta; œdema of pia.

768 (Osler)—Male, 27. November 1st, 1883.

PHTHISIS. Large cavities in both lungs; acute verrucose endocarditis.

769 (Osler)—Female. 18. November 7, 1883.

TYPHOID FEVER. Ulceration of small intestine only; hyperplasia of mesenteric glands and spleen; cloudy swelling of liver; Membranous vaginitis.

770 (Osler)—Male, 31. November 13, 1883.

AMPUTATION OF LEFT LEG; ERYSIPELAS. Warty endocarditis of mitral; spleen slightly enlarged; chronic interstitial nephritis.

771 (Osler)—Male. 25. November 25, 1883.

CHRONIC AORTIC ENDOCARDITIS: ULCERATIVE ENDOCARDITIS OF MITRAL AND AORTIC VALVES. Great hypertrophy and dilatation of heart; acute lobar pneumonia; infarcts of spleen with hyperplasis, 300 grm., spleen enlarged, 600 grm.; old infarcts. Brain, normal.

772 (Osler)—Male, 37. November 29, 1883.

ACUTE LOBAR PNEUMONIA. P. M. invaginations of intestines; acute pericarditis with effusion; seropurulent right pleurisy with effusion and slight area of pneumonia at anterior margin; recent lymph over upper surface of liver.

773 (Osler)—Male, 36. Dec. 5, 1883.

TERTIARY SYPHILIS. Sclerosing osteitis of right tibia and of skull cap, with suppurative periostitis and pachymeningitis. (Only brain entered.)

774 (Osler)—Female, 36. Dec. 5, 1883.

SYPHILITIC THROMBOSIS OF RIGHT MIDDLE CEREBRAL ARTERY.

775 (Osler)—Male, 45. Dec. 9, 1883.

VALVULAR HEART DISEASE.

776 (Osler)—Male, 40. Dec. 17, 1883.

VALVULAR HEART DISEASE. Anasarca Hypertrophy and dilatation of both ventricles; more marked on right side; mitral incompetency; slight fibroid myocarditis; emphysema; brown induration and hypostatic pneumonia; spleen enlarged and hard; granular kidneys with infarcts; chronic catarrhal gastritis.

777 (Osler)—Female. December 17, 1883.

PURULENT ARTHRITIS; PYAEMIA.

778 (Osler)—Female, 26. Dec. 19, 1883.

CHRONIC MITRAL AND AORTIC ENDOCARDITIS. Oedema of lungs with induration; chronic bronchitis and infarcts in lung: cyanotic induration of kidneys; erosions of os uteri; calcification of fimbriae of fallopian tubes; cirrhosis of liver.

779 (Osler)—Male, 25. Dec. 20, 1883.

TYPHOID FEVER. Ulceration of intestines; hyperplasia and infarct of spleen; chronic interstitial nephritis, with cloudy swelling; encysted abscess of lungs, with scattered areas of consolidation.

780 (Osler)—Male, 23. Dec. 26, 1883.

FRACTURE OF LEG, PYAEMIA. Suppurative osteitis; acute septic peritonitis; chronic adhesive pleuritis with interstitial pneumonia; suppurative perinephritis on R. side; (appendicitis (?)) Triangular shape of left kidney.

1884

781 (Osler)—Female, 43. Jan. 12, 1884.

ELEPHANTIASIS OF LABIA PUDENDI, REMOVAL, PYÆMIA. Suppurative arthritis of both wrists; psoriasis of both ankles; slight enlargement of spleen; cloudy swelling of liver; abscesses in left pelvic wall; extensive syphilitic ulcer of rectum with stricture. Recto-vesico-vaginal fistula.

782 (Osler)—5. Jan. 14, 1884.

TUBERCULOUS MENINGITIS. Dropsy of ventricles; lymph and miliary tubercles at the base of brain; miliary tuberculosis of lungs, pleurae, spleen, peritoneum, kidneys and liver, catarrhal gastritis.

783 (Osler)—Female, 3. Jan. 22nd, 1884.

DIPHTHERIA of tonsils and epiglottis; acute capillary bronchitis; recent pleuritic adhesions: uvula bifid; bronchial glands swollen and congested with caseous masses and a few miliary tubercles. Miliary tuberculosis of lungs; broncho-pneumonia; supplementary spleen; miliary tuberculosis of spleen, liver and kidneys; tuberculous enteritis; ecchymosis and hæmorrhagic erosions of stomach.

84 (Osler)—Female, 3. Jan. 30, 1884.

NOMA OF VULVA.

785 (Osler)—Male, 65. Feb. 1, 1884.

FATTY AND CIRRHOTIC liver. Cirrhotic kidneys.

786 (Osler)—Male, 24. Feb. 1st, 1884.

ULCERATIVE ENDOCARDITIS.

787 (Olser)—Male, 65. Feb. 1st, 1884.

MULTIPLE SOFTENING OF BRAIN in left frontal and parietal regions and angular gyrus; subarachnoid œdema and atheroma of arteries; miliary aneurysms; hypertrophy of left side of heart with dilatation and atheroma of valves; atheroma of coronaries; slight atheroma of aorta; dissecting aneurysm of right iliac artery; small granular kidneys; emphysema and œdema of lungs.

788 (Osler)—Male, 40. Feb. 7, 1884.

CANCER OF LIVER.

789 (Osler)—Male, 38. Feb. 7, 1884.

PEMPHIGUS. Sero-purulent pleurisy of left side; bronchitis; perihepatitis fibrosa.

790 (Osler)—Male, 45. Feb. 14, 1884.

ACUTE LOBAR PNEUMONIA, all lobes of right lung; spleen enlarged and soft; catarrhal obstruction of common bile duct; jaundice; cirrhosis of liver; cloudy swelling of kidneys.

791 (Sutherland)—Male, 33. April 14, 1884.

PNEUMOTHORAX. Pulmonary Tuberculosis.

792 (Sutherland)—Male, 1. May 10, 1884.

TUBERCULOUS MENINGITIS.

793 (Sutherland)—Male, 47. May 14, 1884.

PERNICIOUS ANÆMIA.

794 (Sutherland)—Female. May 16, 1884.

DIPTHERIA. Tracheotomy.

795 (Sutherland)—Male, 56. May 2, 1884.

THORACIC ANEURYSM.

796 (Sutherland)—Male, 31. May 16, 1884.

CIRRHOTIC AND FATTY LIVER. Jaundice; obstruction of cystic duct by fibroid thickening; obsolete tubercles in apices of lungs; œdema with partial pneumonia of bases of lungs; old ulceration of larynx; chronic parenchymatous nephritis; jaundice;

797 (Sutherland)—Male, 50. May 21, 1884.

CHRONIC INTERSTITIAL NEPHRITIS. Small granular kidneys; hypertrophy and dilatation of heart (valves normal); œdema of lungs; nutmeg liver.

798 (Sutherland)—Male, 17. May 22, 1884.

TUBERCULOUS PERITONITIS (grape tuberculosis). General tuberculosis; chronic adhesive peritonitis; tuberculous left pleurisy with effusion; atalectasis of left lung; aortic verrucose endocarditis.

799 (Sutherland)—Male, 6. May 21, 1884.

DIPHTHERITIC LARYNGITIS AND TRACHEITIS. Pharynx free; slight broncho-pneumonia.

800 (Sutherland)—Male, 68. May 28, 1884.

CEREBRAL HEMORRHAGE.

801 (Sutherland)—Male, 65. May 30, 1884.

PERNICIOUS ANÆMIA. Dilation of heart; milkpatch; aortic endocarditis: hypertrophy of left heart; hæmorrhagic retinitis.

802 (Sutherland)—Male, 52. June 4, 1884.

CHRONIC INTERSTITIAL NEPHRITIS. Contracted liver; hypertrophy of heart with dilatation; slight cirrhosis of liver; catarrhal gastritis.

803 (Sutherland)—Male, 21. June 8, 1884.

ACTULE LOBAR PNEUMONIA OE RIGHT LUNG. Double acute fibrinous pleurisy; acute fibrinous pericarditis.

804 (Sutherland)—Male, 30. Aug. 14, 1884.

PHTHISIS, with cavities in both lungs; cirrhotic and fatty liver; horseshoe kidney; double hydronephrosis; left pyelonephrosis; calculus in calices and large calculus in pelvis: bladder and urethra healthy.

805 (Sutherland)—Female, 56. Sept. 13, 1884.

TETANUS. Abscess with particle of leather from wound in sole of left foot; acute neuritis of left sciatic nerve with great œdema of sheath.

806 (Sutherland)—Female, 18. Aug. 19, 1884.

TYPHOID FEVER.

807 (Sutherland)—Male 27. Sept. 18, 1884.

PYOPNEUMOTHORAX. Tuberculosis of lungs: seropurulent pleurisy; small perforation communicating with cavity in left apex.

808 (Sutherland)—Female, 42. Oct. 17, 1884.

PERITONITIS. Abscess of liver; chronic perityphlitis (appendicitis ?)

809 (Sutherland)—Male, 28. Oct. 27, 1884.

VALVULAR HEART DISEASE. Hydrothorax; anasarca; cyanotic induration of kidneys; fatty and cirrhotic liver; hyperplasia of spleen with infarcts; milk patch on heart; incompetency of aortic valves; hypertrophy and dilatation of heart; recurrent endocarditis of aortic valves.

810 (Sutherland)—Female, 24. Nov. 13, 1884.

CATARRHAL COLITIS. Scars (from burning?) of face and arms.

811 (Sutherland)—Male, 24. Dec. 5, 1884.

TYPHOID FEVER. Typhoid ulceration of ileum; large firm spleen; fatty liver.

812 (Sutherland)—Female, 19. Dec. 6, 1884.

CHRONIC PARENCHYMATOUS NEPHRITIS. Acute pleurisy; albuminuric retinitis.

815 (Sutherland)—Male, 57. Dec. 10, 1884.

ACUTE RIGHT LOBAR PNEUMONIA. Acute right pleurisy with effusion; cyanotic induration of kidneys; cancerous (?) ulceration of œsophagus below level of bifurcation of trachea.

816 (Sutherland)—Male, 30. Dec. 19, 1884.

HYPERTROPHY AND DILATATION OF HEART. Mitral endocarditis with aneurysm of valve; aortic endocarditis; acute pericarditis; acute localized left pleurisy.

817 (Sutherland)—Male, 65. Dec. 19, 1884.

STRICTURE OF URETHRA. (Pyaemia?) Abscess of penis and prostate; right hydronephrosis; dilatation of bladder.

818 (Sutherland)—Male, 50. Dec. 26, 1884.

MALIGNANT ENDOCARDITIS. Pneumonia; acute meningitis.

819 (Sutherland)—Female, 25. Dec. 23, 1884.

ACUTE LOBAR PNEUMONIA. Anchylosis right knee.

1885

820 (Sutherland)—Male, 31. Feb. 14, 1885.

TUBERCULOSIS. Chronic phthisis; caries of vertebral; tuberculosis and amyloid of liver, kidneys and spleen; thrombosis of left common and external iliac veins.

821 (Sutherland)—Male, 73. Feb. 22, 1885.

CHRONIC INTERSTITIAL NEPHRITIS. Arteriosclerosis; hypertrophy and dilatation of heart; cirrhosis of liver and spleen; anasarca; ascites; hydrothorax.

822 (Sutherland)—Male, 23. Feb. 20, 1885.

CHRONIC PHTHISIS, OF LUNGS. Tuberculous ulceration of larynx and intestine; Caries of body of 5th lumbar vertebra; psoas abscess; tuberculous orchitis.

823 (Sutherland)—Male, 43. Jan. 13, 1885.

CANCER OF STOMACH at pylorus with dilatation; cancerous infiltration of pancreas.

824 (Sutherland)

DYSENTERY. Abscess of liver.

825 (Howard)—Female, 21. March 31, 1885.

TUBERCULOUS PERITONITIS. Laparotomy; adhesions about pelvis and pelvic abscess; miliary tuberculosis of lungs, liver and kidneys.

826 (Howard)—Male, 20. April 11, 1885.

TUBERCULOUS PYOPNEUMOTHORAX. Collapse induration of left lung with adhesive pleuritis; haemothorax; nutmeg liver; fatty kidney; chronic parenchymatous nephritis.

827 (Howard)—Female, 13. April 12, 1885.

ACUTE SEPTIC PERITONITIS. Pyosalpinx. Acute fibrinous pleurisy.

828 (Howard)—Male, 30. May 2, 1885.

ERYSIPELAS. Broncho pneumonia; granular kidneys.

829 (Howard)—Female, 40. May 6, 1885.

CHRONIC PHTHISIS WITH CAVITY. Amyloid spleen; lacing lobe of liver; fatty kidney.

830 (Howard)—Male, 52. May 9, 1885.

BRONCHO PNEUMONIA. Slight interstitial nephritis.

831 (Howard)—Female, 42. May 16, 1885.

CROUPOUS PNEUMONIA right lung; parovarian cyst.

832 (Howard)—Male, 10. May 16, 1885.

DIPHTHERIA. Fatty degeneration of heart; catarrhal laryngitis; broncho pneumonia (convalescence from diphtheria.)

833 (Howard)—Male, 75. May 29, 1885.

CEREBRAL SOFTENING, size of marble, in pons; atheroma of aortic valves and aorta; infarction of spleen; granular kidneys.

834 (Howard)—Male, 63. June 10, 1885.

CANCER OF RECTUM. Secondary in peritoneum, mesenteric and retroperitoneal glands; thrombosis of pelvic veins; broncho pneumonia.

835 (Howard)—Male, 16. June 18, 1885.

CEREBELLAR ABSCESS, (rupture into 4th ventricle); hyperaemia and acute inflation of lungs; granular condition of lateral ventricles and choroid plexus.

836 (Howard)—Female, 50. June 19, 1885.

CEREBRAL HÆMORRHAGE into pons. Large granular kidney (right); uterus bicornus; fibro myomata; almost complete atrophy of left kidney.

837 (Howard)—Male, 45. June 20, 1885.

TUBERCULOSIS PHTHISIS. Universal adhesion of both pleurae; tuberculous pleuritis; phthisis with calcareous change at both apices and miliary tubercles throughout both lungs: œdema of glottis with tuberculous ulceration of larynx; miliary tubercles of trachea; fatty liver.

838 (Howard)—Male, 52. June 23, 1886.

ACUTE LOBAR PNEUMONIA AND CASEOUS PNEUMONIA. Bifid rib left side; yellow caseous tubercles of lungs; small cavity at apex; gray hepatization and caseous pneumonia; fatty liver.

839 (Howard)—Child, 1.

CAPILLARY BRONCHITIS. Atelectasis; fatty liver; rachitis; increase of cerebro-spinal fluid; dilatation of ventricles.

840 (Howard)—Male, 20. July 1, 1885.

RETROPHARYNGEAL ABSCESS. Syphilis; suppurating sinuses of neck; amyloid liver and kidneys.

840 A (Howard)—Male, 29. July 7, 1885.

RECURRENT OSTEOSARCOMA of left leg amputated recently; enlargement of retroperitoneal glands on left side; secondary osteosarcoma of right pleura and lung in form of discs of part of ossified sarcomatous tissue; secondary sarcoma of left lung and pericardium; abdominal viscera free from secondary enlargement.

841 (Howard)—Male, 55. July 2, 1885.

CHRONIC INTERSTITIAL NEPHRITIS.

842 (Howard)—Male. July 9, 1885.

CEREBRAL SOFTENING.

843 (Howard)—Female, 52. July 9, 1885.

STRICTURE OF RECTUM. Peritonitis from perforation of rectum by a bougie; Fibrous cicatrix of rectum; microscopically only fibrous tissue in growth.

844 (Howard)—Male.

FRACTURE OF BASE OF SKULL. Slight intermeningeal hæmorrhage.

844 A (Howard)—Female.

CIRRHOTIC KIDNEY. Atheroma and calcification about heart valves; brown atrophy; fracture of left radius.

845 (Howard)—Male. Died after dilatation of urethra.

STRICTURE OF URETHRA with production passage, lined with smooth gray membrane.

846 (Finley)—Female, 46. July 20, 1885.

PYOSALPYNX. Acute purulent peritonitis; abscess of L. ovary; granular contracted kidney; ulceration and stenosis of rectum.

847 (Finley)—Male.

CIRRHOTIC KIDNEY and amyloid kidney; amyloid liver and spleen.

848 (Finley)—Male.

GLANDERS. Farcy buds of skin.

849 (Finley)—Male, 25. July 19, 1885.

SLOUGHING OF RECTUM.

850 (Finley)—Female, 16. July 16, 1885.

UTERINE SEPSIS. Septichaemia.

851 (Finley)

DIAPHRAGMIATIC HERNIA. From old wound by ribs.

851 A (Finley)—Male, 32. Sept. 29, 1885.

TYPHOID FEVER. Pustular eruption; interstitial nephritis; large spleen.

851 B (Johnston)—Male, 20.

GUNSHOT WOUNDS OF ABDOMEN. Perforation of bowels by Snider bullet at short range; fracture of pelvis; laceration of right iliac veins; broad flat end of second right rib, not bifid.

852 (Johnston)—Male, 46. Oct. 9, 1885.

RECURRENT AORTIC ENDOCARDITIS and incompetency. Atheroma and dilatation of aorta; infarcts in spleen and right lung; chronic interstitial nephritis; embolism of left anterior cerebral artery; ankylosis of right ankle; nutmeg liver.

853 (Johnston)—Male, 29. Oct. 9, 1885.

TYPHOID FEVER. Ulceration of intestines in state of healing; perforation; peritonitis; hypostatic pneumonia; spleen 120 grm.

854 (Johnston)—Private.

DOUBLE FIBRO-CYSTIC SARCOMA of ovary. Secondary sarcoma in peritoneum with adhesive peritonitis, and in glands of portal fissure; jaundice; icterus and cloudy swelling of kidneys with slight hydronephrosis.

855 (Johnston)—Male, 60.

FATTY AND CIRRHOTIC LIVER. Cholæmia (?) jaundice; cholelithiasis.

856 (Johnston)—Male, 21.

SEPTICÆMIA. Poisoning by chlorate of potassium? Suppuration of deep inguinal gland; methæmoglobinæmia; acute parenchymotons nephritis; infarct of spleen. examination of coverslips for bacteria negative; prolongation of left lobe of liver.

857 Details not entered.

858 (Johnston)—Male, 18. Oct. 17, 1885.

TYPHOID ULCERATION of small intestine; enlargement of spleen; croupous pneumonia of right upper lobe and broncho-pneumonia of both lower lobes.

859 (Johnston)—Male, 54. Oct. 17, 1885.

CHRONIC PHTHISIS WITH CAVITY. Tuberculous pleurisy and pericarditis; phthisis with cavity at left apex; fibroid bronchitis and peri-bronchitis; chronic diffuse tuberculous pneumonia of left lower lobe; infarcts of spleen and kidney; tuberculous pyelitis and cystitis; stricture of urethra.

860 (Johnston)—Female, 68. Private. Oct. 19, 1885.

INTESTINAL OBSTRUCTION. Gangrene of bowel, localized peritonitis; obstruction caused by a coil of intestines becoming adherent to a large myoma of the uterus, and twisting round it; slight interstitial nephritis.

861 (Johnston)—Male, 60. Oct. 23, 1885.

PERFORATIVE APPENDICITIS. Perityphlitis from perforation of appendix; local and general septic peritonitis; distension of intestines; hyperæmia of lungs; thickening of aortic and mitral valves.

862 (Johnston)—Male, 25. Oct. 23, 1885.

TYPHOID FEVER. Intestinal hæmorrhage; typhoid ulceration of intestines including the rectum.

863 (Johnston)—Male, 42. Oct. 24, 1885.

ANÆMIA. Bronzing of skin of abdomen; chronic enlargement of liver and spleen; hyperplasia of bone marrow; atheroma of aorta; slight fatty degeneration of heart; cicatrices of colon apparently from former dysentery.

864 (Johnston)—Female, 46. Oct. 29, 1885.

CHRONIC INTERSTITIAL NEPHRITIS. Chronic gastroenteric catarrh; acute general peritonitis; polypus uteri; atrophy of suprarenals; fibroid pleurisy with calcification; hyperplasia of spleen; slight mitral and aortic endocarditis.

865 (Johnston)—Male, 26. Oct. 28, 1885.

ADDISON'S DISEASE. Bronzing of skin for some months; diarrhœa; caseous tubercles in both suprarenals; enlargement of Peyer's patches and solitary follicles; caseous bronchial glands; universal adhesive pericarditis; slight broncho-pneumonia; caseous puckerings at apices of both lungs.

866 (Johnston)—Female, 18. Nov. 1, 1885.

THROMBOSIS. Internal saphenous vein and iliac vein; pulmonary embolism (cause of death.) Apical miliary tuberculosis; anæmia.

868 (Johnston)—Child, 5 days old.

INTESTINAL HÆMORRHAGE. Malæna; source not discovered; icterus; urate infarcts in kidneys.

869 (Johnston)—Male. Private. Nov. 1, 1885.

SCIRRHUS CANCER OF RIGHT KIDNEY. Infiltrating retroperitoneal glands; secondary in omentum; obliterative adhesive appendicitis and perityphlitis.

870 (Johnston)—Female, 29. Nov. 4, 1885.

PULMONARY TUBERCULOSIS. Cavities at each apex; tuberculous peribronchitis and pleurisy; miliary tubercles in liver spleen and kidneys; tuberculous ulceration of intestines.

871 (Johnston)—Male, 38. Nov. 5, 1885.

LACERATION OF ABDOMEN involving spleen, pancreas and left kidney; Hæmorrhagic infarction of lower lobe of left lung; fracture of ribs.

872 (Johnston)—Male, 33. Nov. 6, 1885.

FRACTURE OF BASE OF SKULL through frontal and sphenoid; extra meningeal hæmorrhage; broncho-pneumonia; Meckel's dvierticulum; fusion of lobes of right lung; hypertrophy of heart; thickening of mitral valve. Shipping accident.

874 (Johnston)—Male, 48. Nov. 9, 1885.

CHRONIC TUBERCULOSIS OF BOTH LUNGS. Chronic tuberculous pleuritis; total synechia of pericardium; caseous tubercle of liver; caseation and fibrosis of suprarenals; catarrhal enteritis; milky opacity of pia mater.

876 (Johnston)—Male, 44. Nov. 10, 1885.

CHRONIC PARENCHYMATOUS NEPHRITIS. Commencing interstitial nephritis; fibroid and suppurative orchitis; localized adhesive peritonitis; œdema; ascites; anasarca; deformity of liver; fibrinous pleurisy.

877 (Johnston)—Male, 44. Nov. 12, 1885.

FRACTURE OF SKULL through left temporal, sphenoid and frontal bones; intermeningeal hæmorrhage; fragilitas ossium.

878 (Johnston)—Female, 20. Nov. 25, 1885.

TYPHOID FEVER. Perforation of intestines; hyperæmia and œdema of lungs; acute septic peritonitis.

879 (Johnston)—Female, 37. Nov. 23, 1885.

PHTHISIS. Amputation of left foot for caries; general miliary tuberculosis.

880 (Johnston)—Male. Dec. 4, 1885.

PHTHISIS WITH CAVITIES in both lungs. Thrombus of internal saphena vein, old fracture of second lumbar vertebra.

881 (Johnston)—Female, 25. Dec. 1, 1885.

THROMBOSIS OF CORONARY ARTERY. Thrombosis of left saphena vein; mural thrombus of heart; tertiary syphilis.

882 (Johnston)—Male, 54. Dec. 8, 1885.

PHTHISIS. Large cavities of lungs; tuberculous ulceration of intestines; miliary tubercles of kidneys.

884 (Johnston)—Female, 71. December 9, 1885.

ŒDEMA OF PIA. Degeneration of 5th nerve.

885 (Sutherland)—Male, 35. Dec. 8, 1885.

SYPHILITIC ENDARTERITIS of cerebral arteries: localized meningitis; chronic interstitial nephritis; apical tubercles cicatrised: Meckel's diverticulum; hyperplasia of spleen.

886 (Sutherland)—Male, 45. Dec. 10, 1885.

GONORRHEAL ARTHRITIS. Excision of knee joint; (pyaemia?); chronic adhesive peritonitis; apical nodules in lungs.

887 (Sutherland)—Male, 28. Dec. 12, 1885.

TYPHOID FEVER. Perforation of typhoid ulcer of ileum; acute hyperplasia of spleen; cloudy swelling of kidneys; broncho-pneumonia.

1886

1 (Johnston)—Male, 36. Jan. 13, 1886.

RECURRENT ENDOCARDITIS. Hypertrophy and dilatation of heart; brown induration of lungs; induration of spleen and kidneys; mesenteric glands enlarged and firm; pericardial adhesions.

2 (Johnston)—Female, 10. Jan. 4, 1886.

TYPHOID FEVER. Ulceration of intestines; fatty degeneration of heart; thrombosis of left ventricle; infarct of R kidney; spleen normal; healing typhoid ulcers in intestines; enlarged mesentric glands.

3 (Johnston)—Male, 30. Jan. 6, 1886.

ACUTE MANIA. Hyperæmia and thickening of pia; subarachnoid œdema; other organs normal.

4 (Johnston)—Male, 17. Jan. 13, 1886.

CHRONIC PHTHISIS with cavity. Slight amyloid in kidneys and spleen.

5 (Johnston)—Male, 61. Jan. 22, 1886.

CHRONIC VALVULAR HEART DISEASE. Dilatation and fatty degeneration of heart; sclerotic endocarditis of mitral and aortic valves; hydrothorax; right pleuritis: brown induration of lungs; collapse right lung; indurative hyperplasia of spleen and kidneys; cirrhosis of liver: hypertrophy of prostate; anasarca; icterus.

6 (Johnston)—Male, 38. Jan. 26, 1886.

EPITHELIOMA OF ŒSOPHAGUS. Secondary in lungs; bougie passed into lung? gangrene of lungs; pleurisy; chronic fibrous; perihepatitis.

7 (Johnston)—Male, 80. Jan. 28, 1886.

CHRONIC INTERSTITIAL nephritis. Arteriosclerosis; hypertrophy and dilatation of left ventricle; fusion and sclerosis of aortic and mitral valves; hypertrophy of prostate; chronic catarrhal gastritis.

8 (Johnston)—Male, 43. Jan. 31, 1886.

ACUTE ALCOHOLISM? Cloudy swelling of heart, liver and kidneys; hyperæmia of brain and lungs.

9 (Johnston)—Male, 63. Feb. 5, 1886.

SUPPURATIVE PYONEPHROSIS. Ischiorectal abscess; hypertrophy of prostate; ulcerative cystitis; emphysema; septic embolic pneumonia; anomalies of ascending colon and liver; obliterative phlebitis of hepatic veins with atrophy of left lobe of liver; atheroma of aortic valves.

10 (Johnston)—Infant.

SUDDEN DEATH. Cause not made out; organs appear healthy.

11 (Johnston)—Female, 43. Feb. 13, 1886.

CEREBRAL THROMBOSIS right middle cerebral artery. Sclerotic endocarditis and stenosis of mitral, tricuspid and aortic valves, with fusion of coronary segments; hypertrophy and dilatation of heart; emphysema; infarcts of spleen; nutmeg liver; chronic adhesive pelvic cellulitis and peritonitis; right pyelonephritis from uric acid calculus.

12 (Johnston)—Male, 6. Feb. 13, 1886.

ACUTE TUBERCULOUS MENINGITIS. Meningeal hæmorrhage; acute miliary tuberculosis of both lungs, with caseous bronchial glands; miliary tuberculosis of liver, spleen and kidneys; localized tuberculous pleuritis and peritonitis; tuberculous follicular ulceration of intestines.

13 (Johnston)—Private, Male, 7 months. Feb. 22, 1886.

ASPHYXIA FROM FOOD in air passages.

14 (Johnston)—Male, 40. March 4, 1886.

SUICIDE BY REVOLVER WOUND OF SKULL. Laceration of frontal lobes; meningeal hæmorrhage; acute tuberculous pleurisy; phthisis of both lungs; hypostatic pneumonia; distended gall bladder; no obstruction.

15 (Johnston)—Female, 75. Feb. 28, 1886.

THROMBOSIS OF CORONARY ARTERY. Myomalacia cordis; acute aneurysm of left ventricle; rupture into pericardium; atheroma and aneurysm of abdominal aorta; lacing deformity of liver and intestines; chronic suppurative arthritis right elbow; cellulitis right arm; dextro position of rectum.

16 (Johnston)—Female, 40. Feb. 14, 1886.

CANCER OF STOMACH at pylorus, with stenosis and gastrectasia.

17 (Johnston)—Male, 53. March, 7, 1886.

CALCULI OF BLADDER. Lithotomy incision and sinus in perineum; suppurative pyelitis with calculus: hypertrophy of prostate; chronic cystitis with sacculation and calculi of bladder; emphysema; bronchopneumonia; perisplenitis; stenosing phlebitis of R. renal vein.

18 (Johnston)—Female, 20. March 9, 1886.

PUERPERAL SEPTICÆMIA. Subinvolution; puerperal state; acute purulent peritonitis; hæmorrhagic diphtheritic endometritis; acute pleurisy, with effusion; cloudy swelling of liver and kidneys; hyperplasia of spleen.

19 (Johnston)—Male, 65. March 15, 1886.

FRACTURE OF SKULL. Meningeal hæmorrhage; lateral dislocation of axis; diverticulum of bladder; hyperæmia of lungs.

20 (Johnston)—Male, 34. March 19, 1886.

SUPPURATIVE APPENDICITIS with perforation; pylephlebitis and hepatic abscess.

21 (Johnston)—Male, 25. March 27, 1886.

CHRONIC VALVULAR HEART DISEASE. Sclerotic and verrucose mitral endocarditis; pericardial synechiæ; hypertrophy of heart. (Partial autopsy.)

22 (Johnston)—Male, 21. March 13, 1886.

STRANGULATED R. INGUINAL HERNIA (reduced). Localized septic peritonitis; necrosis of intestine and strangulation from constriction of loop of bowel by old adhesions, (loop 18″ long); left inguinal hernia.

23 (Johnston)—Male, 47. April 5, 1886.

ULCERATIVE ENDOCARDITIS of aortic valves; hypertrophy and dilatation of heart; acute pericarditis (local); acute pneumonia; infarcts of lung; acute fibrinopurulent (septic) meningitis.

24 (Johnston)—Male, 41. April 6, 1886.

HYPERTROPHY AND DILATATION OF HEART. Chronic sclerotic aortic endocarditis; dilatation and atheroma of aorta; obsolete caseous apical tubercles; scar of glans.

25 (Johnston)—Male, 33. April 12, 1886.

CRUSH OF CHEST. Dislocation of 1st costal, cartilage; ecchymosis of pericardium; double pneumonia; acute right pleurisy.

26 (Johnston)—Male, 28. April 14, 1886.

ACUTE LOBAR PNEUMONIA. Follicular ulcers of colon.

27 (Johnston)—Male, 54. April 17, 1886.

CARCINOMA OF PANCREAS, secondary in liver, lungs, kidneys and duodenum; gall-stones; intestinal hæmorrhage; cirrhotic kidneys; old ulcer of leg.

29 (Johnston)—Private. April 26, 1886.

GLIOSARCOMA OF PITUITARY BODY. Atrophy of optic nerves; chronic hydrocephalus.

28 (Johnston)—Private. April 25, 1886.

TUBERCULOUS PYONEPHROSIS of right kidney and ureter; tuberculous cystitis; tuberculous right suprarenal; tuberculous vesicles; pulmonary phthisis.

30 (Johnston)—Female. Private. April 26, 1886.

PULMONARY EMBOLISM FROM UTERINE THROMBOSIS. Subinvolution; puerperal state; thrombosis of veins of uterine plexus, pelvic and iliac veins and inferior vena cava; pulmonary embolism; septic endocarditis; local septic pelvic peritonitis; acute hyperplasia of spleen; cloudy swelling of heart, liver and kidneys.

31 (Johnston)—Female, 22. April 27, 1886.

PUERPERAL SEPTICÆMIA. Mycotic aortic endocarditis; streptococus infection; infarcts of spleen and kidneys: cloudy swelling of liver and kidneys; acute hyperplasia of spleen.

33 (Johnston)—Male, 6. April 30, 1886.

ACUTE CEREBRO SPINAL MENINGITIS (non-tuberculous).

34 (Johnston)—Male, 32. May 1, 1886.

PULMONARY PHTHISIS. Chronic tuberculous pleuritis; tuberculous ulceration of intestine; chronic lepto-meningitis with granulomata of ependyma; chronic parenchymatous and interstitial nephritis.

35 (Johnston)—Female, 20. May 3, 1886.

TUBERCULOUS SALPINGITIS. General acute purulent tuberculous peritonitis and pleuritis; milk patch of pericardium; tuberculosis of lungs and kidneys.

36 (Johnston)—Female, 26. May 4, 1886.

ACUTE TUBERCULOSIS OF LUNGS. Hyaline degeneration of spleen, liver and kidneys; fistula in ano and hæmorrhoids; tuberculous ulcers of duodenum, jejunum and cæcum; chronic purulent otitis media; bedsores; dilatation of heart: sclerotic endocarditis of tricuspid valve and recurrent mitral endocarditis.

37 (Johnston)—Male, 28. May 5, 1886.

CHRONIC PARENCHYMATOUS NEPHRITIS. Fatty and cirrhotic liver; alcoholism; atheroma of aorta; hyperæmia of lungs; anasarca; ascites; jaundice.

38 (Johnston)—Male, 26. May 7, 1886.

PULMONARY PHTHISIS, large cavities in each lung; tuberculous ulceration through whole length of intestine; tuberculous kidney; polypoid adenoma of duodenum; tubercles in suprarenals; verrucose endocarditis; tuberculosis of mesenteric glands.

39 (Johnston)—Female, 19. May 7, 1886.

TUBERCULOUS PHTHISIS OF LUNGS, large cavities; amyloid spleen, liver and intestines; concretion in vermiform appendix; tuberculous ulcers of larynx and ascending colon.

40 (Johnston)—Private.

DELIRIUM TREMENS, ALCOHOLISM. Subarachnoid œdema of brain; no meningitis. (Other organs not examined).

41 (Johnston)—Male, 50. May 10, 1886.

TUBERCULOSIS OF LUNGS. Tuberculous pleurisy; tuberculous ulceration of intestines, with perforation; peritonitis; tubercle of R adrenal; leucoderma; inguinal hernia; tubercles of kidneys.

42 (Johnston)—Male, 40. May 14, 1886.

CHRONIC ULCERATIVE PHTHISIS of lungs, larynx and intestines; tuberculosis of suprarenals; amyloid liver, spleen, kidneys and intestines; sclerotic mitral and verrucose aortic endocarditis; dilatation of tricuspid.

43 (Johnston)—Female, 50. May 15, 1886.

EMBOLISM R. MIDDLE CEREBRAL artery and softening of right corpus striatum, central lobe and internal capsule; sclerotic mitral and verrucose aortic endocarditis; chronic parenchymatous nephritis; infarction of kidney; amyloid (bacon) spleen; subperitoneal fibromyoma of uterus; amputation of right breast (one year previous); secondary cancer of left lung.

44 (Kirkpatrick)—Male, 45. May 17, 1886.

ACUTE LOBAR PNEUMONIA both lower lobes; acute double pleurisy; atheroma of aortic valves, with fusion; jaundice.

45 (Johnston)—Female, 12. May 18, 1886.

DIPHTHERIA of larynx, pharynx and trachea; tracheotomy; cellulitis of neck.

46 (Howard)—Male, 65. May 20, 1886.

ACUTE PLEURISY; collapse and œdema of lungs; atheroma of mitral and aortic valves; calcified apical tuberculosis.

47 (Howard)—Female, 42. May 23, 1886.

GRANULAR KIDNEYS. Hæmorrhage right corpus striatum, hypertrophy of heart; arteriosclerosis; acute pleurisy and pneumonia; retroversion of uterus; rectum on right side.

48 (Howard)—Male, 60. May 24, 1886.

LYMPHOSARCOMA? of right lung and pleura; nodules in kidneys, suprarenals and left lung.

49 (Howard)—Male, 45. June 1, 1886.

CHRONIC INTERSTITIAL NEPHRITIS. Hypertrophy of heart, with dilatation.

50 (Howard)—Female, 32. June 1, 1886.

TUBERCULOSIS OF LUNGS, WITH CAVITIES. Tuberculous peritonitis; fatty liver.

51 (Howard)—Male, 57. June 20, 1886.

UNDILATED STRICTURE OF URETHRA. Recent false passage; intense hyperæmia of lungs; kidneys enlarged and congested.

52 (Howard)—Female, 31. June 20, 1886.

CHRONIC PHTHISIS. Tuberculous ulceration of larynx, lungs and intestines; periurethral abscess; adhesive peritonitis.

53 (Howard)—Male, 36. June 26, 1886.

INTESTINAL OBSTRUCTION. Alcoholism; jaundice.

54 (Howard)—Male, 34. Sept. 23, 1886.

HÆMORRHAGE RIGHT SIDE OF BRAIN. Hæmorrhagic infarcts in lungs; Subpericardial and subcutaneous ecchymosis.

55 (Johnston)—Male, 22. Oct. 21, 1886.

TYPHOID FEVER. Ulceration of intestines in late stage; hyperplasia of spleen; slight parenchymatous degeneration of liver and kidneys; hæmorrhagic pericarditis (with miliary tuberculosis).

56 (Johnston)—Male, 52. Oct. 26, 1886.

COLLOID CANCER OF RECTUM. Secondary in inguinal and retroperitoneal glands and in lung; chronic and acute tuberculosis of lungs.

57 (Johnston)—Female, 42. Oct. 27, 1886.

CRIMINAL ABORTION. Traumatic septic endometritis; subinvolution; status puerperalis; infarction and septic pneumonia of lungs; acute fibrinous pleurisy; hyperplasia of spleen; cloudy swelling of liver, kidneys and heart; suppurative parotitis.

58 (Johnston)—Male, 35. Oct. 30, 1886.

FRACTURE OF PELVIS. Derrick accident. Laceration of urethra; urinary infiltration and phlegmonous cystitis; fracture of ribs: acute pleurisy; septicæmia.

59 (Johnston)—Female, infant.

SEPTICHÆMIA? Petechial rash. Nothing special in appearance of organs.

60 (Johnston)—Male, 33. Nov. 1, 1886.

INTESTINAL OBSTRUCTION. Adhesive local peritonitis; appendix attached to kink of ileum; acute gastro-enteritis; gall-stones.

61 (Johnston)—Female, 8 days.

SEPTICÆMIA. Child of leukaemic mother; gastroenteritis; purpura.

62 (Johnston)—Male, 43. Nov. 1, 1886.

CEREBRO SPINAL MENINGITIS? Broncho pneumonia; chronic catarrhal gastritis; chronic interstitial nephritis; cirrhosis of liver.

63 (Johnston)—Female, 50. Nov. 10, 1886.

HYPERTROPHY AND DILATATION OF HEART, non-valvular; anasarca; hydrothorax; hydropericardium; ascites; chronic interstitial nephritis; cyst of kidney; lacing lobe of liver; chronic pelvic adhesive peritonitis; arteriosclerosis; Meckel's diverticulum.

64 (Johnston)—Private. Nov. 12, 1886.

CHOLELITHIASIS. Perforation of gall bladder; gallstone obstructing common bile duct; jaundice; chronic local peritonitis; acute general septic peritonitis.

65 (Johnston)—Male, 27. Nov. 12, 1886.

FRACTURE OF SKULL. Derrick accident. Laceration and contusion of scalp; depressed fracture of L. parietal bone; rupture of left middle meningeal artery; inter and extra meningeal hæmorrhage; orbital hæmorrhage; œdema of lungs.

66 (Johnston)—Private.

CANCER OF STOMACH, with ulceration; secondary cancer of pancreas and retroperitoneal glands; secondary cancer of right lung and liver; peritonitis; cancerous pleurisy.

67 (Johnston)—Male, 45. Nov. 16, 1886.

EPITHELIOMA OF ŒSOPHAGUS. Secondary in bronchial glands and left bronchus.

68 (Johnston)—Female, 74. Nov. 16, 1884.

BRONCHO-PNEUMONIA. Fibroid pleurisy; chronic endocarditis; gall stone; abscess of brain.

69 (Johnston)—Female, 38. Nov. 18, 1886.

ALCOHOLISM; PERIPHERAL NEURITIS.

70 (Johnston)—Male, 22. Nov. 20, 1886.

TUBERCULOUS PYELITIS. Old right lateral lithotomy and cystitis; perineal fistula; caseous prostatitis and epididymitis; acute tuberculosis of both lungs; chronic left pleurisy; amyloid spleen, liver, kidneys and intestines.

71 (Johnston)—Female, 29. Nov. 25, 1886.

CHRONIC MYELITIS. Slaty pigmentation of follicles in jejunum; cystic ovary.

72 (Johnston)—Male, 52. Nov. 29, 1886.

SCIRRHOUS CANCER OF PYLORUS. Dilatation of stomach.

73 (Johnston)—Male, 41. Nov. 30, 1886.

NON-VALVULAR DILATATION AND HYPERTROPHY of heart. Slight fatty change of heart muscle; acute miliary tuberculosis of lungs, liver and kidneys; tuberculous endocarditis; tuberculous ulceration of colon.

74 (Johnston)—Female, 20. Nov. 30, 1886.

EMBOLISM OF LEFT SYLVIAN ARTERY. Verrucose endocarditis of mitral; white softening of brain; acute parenchymatous nephritis.

75 (Johnston)—Male, 38. Nov. 30, 1886.

CHRONIC PULMONARY PHTHISIS, cavity left lung; chronic caseous peribronchitis; tuberculous right pleurisy; tuberculous ulcers of intestine.

76 (Johnston)—Private.

CANCER OF PYLORUS. Dilatation of stomach.

78 (Johnston)—Female, 40. Dec. 6, 1886.

CEREBRAL SOFTENING and calcareous change in brain; calcified nodule in pons; chronic myelitis.

79 (Johnston)—Male, 24. Dec. 6, 1886.

CHRONIC TUBERCULOSIS OF LUNGS and intestine. Local tuberculous peritonitis; amyloid spleen, liver and kidneys.

80 (Johnston)—Male, 26. Dec. 7, 1886.

ACUTE MENINGITIS and chronic lepto-meningitis; hyperæmia of lungs and kidneys.

81 (Johnston)—Male, 54. Dec. 10, 1886.

ACUTE LOBAR PNEUMONIA, with interstitial pneumonia. Subacute pericarditis and pleurisy; cysts in kidneys; hypertrophy of middle lobe of prostate.

82 (Johnston)—Male, 19. Dec. 12, 1886,

TYPHOID FEVER. DIPHTHERIA. Ulceration of intestines; acute hyperplasia of mesenteric glands and spleen; diphtheria of pharynx, larynx and trachea; broncho-pneumonia of upper lobe of left lung; atrophy of left inner temporal convolution.

83 (Johnston)—Male, 41.

DIFFUSE ANEURYSM OF INNOMINATE ARTERY. Erosion of sternum; obliteration of superior vena cava, with dilatation of veins; pressure on right vagus; broncho-pneumonia.

84 (Johnston)—Female, 32. Dec. 23, 1886.

PHTHISIS. Cavities in both lungs; amyloid spleen, liver, kidneys and intestines; acute parenchymatous nephritis.

85 (Johnston)—Male, 50. Dec. 18, 1886.

SUPPURATIVE NEPHRITIS. Enlarged prostate and abscess of prostate; hyperplasia of spleen; pyæmia.

86 (Johnston)—Male 45. Dec. 16, 1886.

ANEURYSM OF AORTA.

87 (Johnston)—Male, 42. Dec. 31, 1886.

FRACTURE AND DISLOCATION OF DORSAL VERTEBRA.

1887

1 (Johnston)—Femals, 50. Jan. 14, 1887.

RECURRENT CARCINOMA OF MAMMA. Cancerous thrombus in left subclavian vein; secondary cancer in lungs and liver; chronic hydrocephalus internus; chronic mitral endocarditis.

2 (Johnston)—Female, 19. Jan. 20, 1887. Maternity.

PYÆMIA. Acute peritonitis and pleurisy: puerperal state; subinvolution; diphtheritic endometritis; streptococcus infection; purulent arthritis of wrist; cloudy swelling of liver and spleen; acute hyperplasia of spleen; catarrhal enteritis; follicular tonsilitis.

3 (Johnston)—Female, 11. Jan. 26. 1887. Dr. Ross.

ACUTE TUBERCULOUS MENINGITIS. Solitary tubercle of cerebellum; sub-acute tuberculous peritonitis; slight miliary tuberculosis of lungs, liver and kidneys; double optic neuritis; anchylosis of ankle; ovarian cysts; miliary tubercles of intestines.

4 (Johnston)—Male, 22. Jan. 26, 1887. Dr. Roddick.

COMPOUND COMMINUTED FRACTURE THROUGH LEFT KNEE. Fracture of R. Femur, tibia and fibula, R. ulna and radius; prolongation left lobe of liver; lobulation of kidneys; atheroma of mitral valve; enlarged solitary follicles of ileum.

5 (Johnston)—Male, 28. Jan. 26, 1887. Drs. Ross and Bell.

MILIARY TUBERCULOSIS of lungs, liver, spleen and kidneys. Apical tubercle (caseous); right tuberculous pyelitis; tuberculous urethro perineal rectal fistula; R. tuberculous epididymitis; ablation left testicle; tuberclosis of suprarenals; bedsores; acute tuberculous meningitis.

6 (Johnston)—Female, 52. Jan. 27, 1887. Dr. Molson.

ACUTE PLEURISY, WITH BRONCHITIS AND CONGESTION OF BOTH LUNGS. Parenchymatous and chronic interstitial nephritis; fibromata of kidneys; atheroma of aorta; pulmonary apoplexy.

7 (Johnston)—Female, 22. Private.

PERIPHERAL NEURITIS. Caseous area in lower lobe of left lung.

8 (Johnston)—Male, 38. Feb. 11, 1887. Dr. Bell.

CARCINOMA OF STOMACH, secondary in omentum retroperitoneal glands and liver; cancerous degeneration of marrow of ribs and sternum, caries of 1st and 6th dorsal vertebræ.

9 (Johnston)—Female, 70. Feb. 14, 1887. Dr. Molson.

BRONCHO-PNEUMONIA. Atheroma of coronary arteries and general arteriosclerosis nodosa, hypertrophy of left ventricle; fatty degeneration of heart; chronic bronchitis: granular kidneys.

10 (Johnston)—Male, 26. Feb. 15, 1887.

DOUBLE CALCULOUS PYELITIS. Nephrolithotomy; obliteration of L. ureter; acute swelling of retro-abdominal lymph glands; icterus.

11 (Johnston)—Male, 20. Feb. 17, 1887. Dr. Ross.

PHTHISIS, WITH CAVITIES IN BOTH LUNGS. Chronic adhesive pleuritis; tuberculous ulceration of ileum; appendix dilated, 10 c.m. in circumference.

12 (Johnston)—Male, 65. Feb. 17, 1887.

CHRONIC TUBERCULOSIS OF LUNGS. Brown atrophy of heart; dilatation of aorta, with atheroma; brown atrophy of liver; softening of brain; tuberculosis of thoracic duct.

13 (Johnston)—Female, 25. Feb. 20, 1887. Maternity.

ACUTE SEPTIC ENDOMETRITIS AND PERIMETRITIS. Puerperal fever; laparotomy; acute septic pleurisy; cyst of broad ligament; cloudy swelling of heart, liver and kidneys; acute hyperplasia of spleen; streptococcus infection.

14 (Johnston)—Female, 65. Feb. 24, 1887. Private.

DISSEMINATED ATROPHY OF CORPORA STRATIA WITH CYSTS.

15 (Johnston)—Female, 40. Feb. 24, 1887. Maternity.

PUERPERAL SEPTICÆMIA. Streptococcus infection; diphtheritic endometritis; phlegmonous parametritis and perimetritis; acute sero-purulent peritonitis; cloudy swelling of liver and kidneys; hyperplasia of spleen.

16 (Johnston)—Male, 22. Feb. 27, 1887. Dr. Molson.

CHRONIC TUBERCULOSIS OF LUNGS WITH CAVITIES. Tuberculous ulceration of larynx and trachea, small intestine and rectum: enlargement of mesenteric glands: brown atrophy of liver; pediculi capitis and pubis.

17 (Johnston)—Child, 3 months. Feb. 28, 1887. Private.

ŒDEMA OF GLOTTIS. Sudden death. Hyperæmia of lungs; subacute laryngitis and bronchitis; rachitis; anæmia; anasarca; syphilis?

18 (Johnston)—Fœtus. Feb. 10, 1887. Private.

HYDRAMNIOS. Organs normal.

19 (Johnston)—Female, 20. Maternity.

PUERPERAL SEPTICÆMIA. Lactation; diphtheritic endometritis; acute septic peritonitis and pleurisy; chronic ovaritis fibrosa; acute hyperplasia of spleen; pharyngeal diphtheria; streptococcus infection.

20 (Johnston)—Female, 50. March 14, 1887. Dr. Bell.

WOUND OF NECK, PERFORATING LEFT PLEURA. Compound fracture of sternum and both first ribs; acute sero-fibrinous hæmorrhagic pleurisy; acute pericarditis; compression of R. sub-clavian artery; fatty liver.

21 (Johnston)—Male, 60.

FRACTURE OF RIGHT RIBS, 1ST TO 9TH, AND LEFT, 1ST TO 3RD; HÆMOTHORAX. Emphysema: chronic productive pachy-and lepto-meningitis; R. inguinial hernia; double hydrocele; Meckel's diverticulum. (Coroner's case. Verdict: Death from natural causes!)

22 (Johnston)—Male, 50. March 15, 1887. Private.

CEREBRAL HÆMORRHAGE RIGHT CORPUS STRIATUM; HÆMORRHAGE INTO VENTRICLES. Alcoholic. (Only brain examined).

23 (Johnston)—March 22, 1887. Private.

GLIO-SARCOMA OF R. FRONTAL LOBE OF BRAIN. Pericardial and pleuritic synechiæ; arterio-sclerosis; catarrhal enteritis and gastritis; emphysema; hypostatic broncho-pneumonia; granular kidneys; parenchymatous nephritis.

25 (Johnston)—Male, 30. April 22, 1887. Dr. McDonnell.

CHRONIC PARENCHYMATOUS AND INTERSTITIAL NEPHRITIS. Anæmia; anasarca; ascites; chronic hyperplasia of spleen; gastro-enteritis; fatty heart; slight acute pericarditis.

26 (Johnston)—Female, 17. April 26, 1887. Dr. Wilkins.

NON-TUBERCULOUS ACUTE BASILAR MENINGITIS.

27 (Johnston)—Male, 7. April 28, 1887.

FRACTURE OF SKULL, temporal and frontal bones; trephining; purulent otitis and pachymengitis; abscess of brain; purulent otitis media.

28 (Johnston)—Male, 30. April 30, 1887. Dr. MacDonnell.

RENAL CALCULUS. Double hydronephrosis.

29 (Johnston)—Male. May 10, 1887. Dr. Wilkins.

CHRONIC SCLEROTIC AND ACUTE VERRUCOSE ENDOCARDITIS, WITH STENOSIS. Acute pleurisy, with effusion; localized empyæma: acute local peritonitis; acute pericarditis: ateleclasis left lung; infarct of spleen and R. kidney.

30 (Johnston)—Male, 55. May 10, 1887. Dr. Wilkins.

CHRONIC ULCERATIVE PHTHISIS, with acute miliary tuberculosis and emphysema; adhesive pleurisy; brown atrophy of heart.

31 (Johnston)—Female, 32. May 12, 1887. Dr. Wilkins.

CHRONIC PHTHISIS OF LUNGS.

31 a (Johnston)—Male, 17½ months. Private.

NASAL AND PHARYNGEAL DIPHTHERIA. Atelectasis R. lung; p. m. invagination of bowel.

32 (Johnston)—Male, 88. May 11, 1887. Dr. MacDonnell.

PYELONEPHROSIS AND HYDRONEPHROSIS. Hypertrophy of prostate; dilatation of bladder; depressed fracture of R. frontal bone (healed).

33 (Johnston)—Female, 12. Private.

PERFORATIVE APPENDICITIS. Pericæcal abscess; acute peritonitis; ascarides.

34 (Johnston)—Female, 35. May 12, 1887. Dr. Wilkins.

CHRONIC ULCERATIVE PHTHISIS. Tuberculous fibrous pleuritis; tubercular ulceration epiglottis; hypertrophy of right ventricle; brown atrophy of heart; nutmeg liver; tuberculous ulceration of intestines; amyloid spleen, liver, kidneys and intestines.

35 (Johnston)—Male, 53. May 16, 1887.

EPITHELIOMA OF ŒSOPHAGUS, infiltrating trachea; pressure on recurrent nerves; purulent bronchitis; chronic adhesive local pleurisy; calcerous bronchial glands; chronic mitral endocarditis: brown atrophy of heart; granular atrophic kidney.

36 (Johnston)—Male, 28. May 18, 1887.

PHLEGMONOUS CELLULITIS and lymphangitis L. arm. Universal adhesive R. pleuritis; multiple apoplexy of lungs; slight sclerotic mitral endocarditis; fatty liver; cloudy swelling of liver and kidneys: condylomata of penis.

37 (Johnston)—Male, 36. May 23, 1887.

TUBERCULOUS ULCERATIVE PHTHISIS. Chronic and acute tuberculous pleurisy; tuberculous pharyngitis? chronic adhesive pericarditis; fatty liver.

38 (Johnston)—Female, 30. May 26, 1887. Dr. Wilkins.

PHTHISIS, WITH CAVITY OF LEFT LUNG. Ochre degeneration of fat; R. pleurisy with effusion; acute broncho-pneumonia; œdema of lungs; abscess and fistula of vulva; hæmorrhoids; hæmorrhagic spot (tuberculous) on epiglottis.

39 (Johnston)—Male, 36. May 27, 1887. Dr. MacDonnell.

PULMONARY PHTHISIS, cavity in left upper lobe; tuberculous pleuritis; adhesive pericarditis; tuberculous peritonitis and enteritis; amyloid of spleen, liver, kidneys, stomach, intestines and bladder.

40 (Johnston)—Female, 17. Nay 27, 1887. Drs. Buller and MacDonnell.

CHRONIC INTERSTITIAL NEPHRITIS. Hypertrophy of heart; mitral stenosis; œdema of lungs, with pulmonary apoplexy; infarct of spleen; pigmentation of peritoneum; retinitis and bulbar neuritis.

41 (Johnston)—Female, 31. June 6, 1887.

RECURRENT SCLEROTIC AND VERRUCOSE ENDOCARDITIS WITH MITRAL STENOSIS. Parenchymatous myocarditis: subinvolution; chronic endometritis; infarcts of lung and kidney; gallstones; cirrhosis of liver infarcts of spleen; status puerperalis.

42 (Johnston)—Male, 40. June 13, 1887. Dr. MacDonnell.

ATHEROMA OF AORTA, DIFFUSE ANEURYSM OF TRANSVERSE ARCH. Dilatation and hypertrophy of heart; infarction of left lung; left hydrothorax; ulcer of R. ankle.

43 (Johnston)—Male, 57. June 15, 1887. Dr. Wilkins.

CHRONIC PHTHISIS OF LUNGS.

44 (Johnston)—Male, 46. June 16, 1887. Private.

CHRONIC AORTIC AND MITRAL ENDOCARDITIS, WITH STENOSIS. Chronic adhesive peritonitis; induration of spleen and kidneys; cirrhosis of liver; ascites; anasarca; hydrothorax.

45 (Johnston)—Female, 26. June 18, 1887. Dr. Wilkins.

URAEMIC COMA; chronic pleuritis and pericarditis; hogback kidney; multiple angioma of liver; acute hyperplasia of spleen; R. hydrosalpinx; chronic adhesive pelvic peritonitis.

46 (Johnston)—Male, 5. June 18, 1887. Dr. MacDonnell.

DIPHTHERIA of pharynx, larynx and trachea; broncho-pneumonia.

47 (Johnston)—Female, 22. June 20, 1887. Dr. Wilkins.

PULMONARY PHTHISIS WITH CAVITIES. Amyloid of spleen, liver, kidneys and intestines; tuberculous laryngitis; round ulcer of stomach.

48 (Johnston)—Male, 33. June 22, 1887. Dr. Roddick.

FRACTURE OF CERVICAL VERTEBRÆ. Acute double pleurisy; broncho-pneumonia.

49 (Johnston)—Female, 78. June 26, 1887.

COMMINUTED FRACTURE OF RIGHT FEMUR. Chronic bronchitis with emphysema; fat infiltration of heart; senile kidneys; Liebermeister's furrows of liver; papilloma of bladder.

50 (Johnston)—Male, 22. Private.

APPENDICITIS, (perforative) with abscess: general purulent peritonitis; old adhesive perityphlitis and peritonitis; fæcal concretion in appendix.

51 (Johnston)—Male, 21. June 29, 1887. Dr. Wilkins.

PULMONARY PHTHISIS CAVITIES IN BOTH LUNGS. Emphysema and œdema; tuberculous laryngitis; tuberculous enteritis.

52 (Johnston)—Female, 26. June 29, 1887. Dr. Wilkins.

CHRONIC SUPPURATIVE PELVIC CELLULITIS. Subinvolution; thrombosis of pelvic and iliac veins and vena cava; hyperæmia and œdema of lungs.

53 (Johnston)—Male, 50. July 6, 1887. Dr. MacDonnell.

TYPHOID FEVER. Ulceration of small and large intestines: perforation; peritonitis.

54 (Johnston)—Female, 23. July 7, 1887. Maternity.

LACERATION OF LEFT URETER DURING LABOUR. Flat pelvis; fistula of ureter and abscess of left flank; diphtheritic vaginitis; acute pyonephrosis, severe on left side, slight on right. Forceps case.

55 (Johnston)—Male, 42. July 8, 1887. Dr. Roddick.

ACUTE TUBERCULOSIS OF BOTH LUNGS. L. empyæma; tuberculous abscess in liver, with fistula perforating sternum and leaving sinus.

56 (Lafleur)—Male, 23. July 9, 1887.

FRACTURE AND DISLOCATION OF 5TH CERVICAL VERTEBRA.

57 (Johnston)—Male, 34. July 11, 1887. Dr. Wilkins.

TYPHOID FEVER. Ulceration of bowel; bronchitis and emphysema; perichondritis; abscess in spleen.

58 (Johnston)—Male, 27. Aug. 8, 1887.

TYPHOID. Ulceration of ileum; acute hyperplasia of spleen; acute parenchymatous nephritis; p. m. invagination; cloudy swelling of kidneys.

60 (Johnston)—Female, 25. Sept. 6, 1887. Dr. MacDonnell.

ARSENICAL POISONING. Rough on rats. Round ulcer of stomach; chronic follicular enteritis; chronic adhesive peritonitis; perimetritis and salpyngitis.

61 (Johnston)—Male, 55. Sept. 14, 1887. Dr. Wilkins.

ATROPHIC CIRRHOSIS OF LIVER. Double pleuritic adhesions; chronic gastritis; apical cicatrices of lungs; icterus.

62 (Johnston)—Male, 30. Sept. 16, 1887. Dr. MacDonnell.

TYPHOID FEVER, with ulceration and diffuse catarrhal enteritis; acute localized peritonitis (no perforation); acute bronchitis; hyperplasia of spleen.

63 (Johnston)—Male, 43. Sept. 21, 1887. Dr. Wilkins.

CHRONIC INTERSTITIAL NEPHRITIS. Chronic hypertrophic catarrhal gastritis; hypertrophy of heart; Œdema of lungs; R. hydrothorax; anasarca; polypoid adenomata of rectum.

65 (Johnston)—Male, 65. Sept. 22, 1887. Dr. Fenwick.

FRACTURE OF FRONTAL AND SPHENOID BONES, BASE OF SKULL. Laceration and hæmorrhage (extra and inter meningeal) from middle meningeal artery; slight laceration of brain; atheroma of aorta; anchylosis of dorsal vertebræ.

66 (Johnston)—Male, 30. Sept. 22, 1887.

DIPHTHERIA of pharynx and fauces.

67 (Johnston)—Female, 52. Sept. 23, 1887. Dr. Wilkins.

MITRAL STENOSIS. Dilatation of left auricle; fatty degeneration of heart; emphysema; fibromyoma uteri; granular kidneys; infarct of kidney.

68 (Johnston)—Female, 27. Sept. 23, 1887.

TYPHOID FEVER. Acute hyperplasia of spleen; ulceration of intestines; apoplexy of lungs; acute hyperplasia of mesenteric glands; cloudy swelling of liver and kidneys; angioma of liver.

69 (Johnston)—Male, 23. Sept. 24, 1887. Dr. Wilkins.

CHRONIC PULMONARY PHTHISIS. Tuberculous; caseous bronchial glands; miliary tubercles of liver and kidneys.

70 (Johnston)—Male, 74. Sept. 24, 1887. Dr. Fenwick.

HYPERTROPHY OF PROSTATE. Hypertrophy of bladder; chronic catarrhal bronchitis; chronic gastritis; ascarides; icterus; (kidneys not dilated).

71 (Johnston)—Male, 24. Sept. 27, 1887. Dr. Wilkins.

TYPHOID FEVER. Ulceration and perforation of ileum; follicular typhoid ulcer of colon; acute peritonitis; acute hyperplasia of spleen; acute broncho-pneumonia; purulent otitis media.

72 (Johnston)—Male, 27. Sept. 27, 1887. Dr. Wilkins.

TYPHOID FEVER. Ulceration of ileum; hyperplasia of spleen and mesenteric glands; broncho-pneumonia.

73 (Johnston)—Male, 18. Sept. 30, 1887.

TYPHOID FEVER. Slight localized peritonitis; acute swelling of spleen and mesenteric glands; cloudy swelling of kidneys; fatty liver; adenoma of supra-renal; old tuberculous adenitis of glands of neck.

74 (Johnston)—Male, 74. Oct. 4, 1837.

PYÆMIA. ACUTE CELLULITIS and abscess of left leg. Purulent arthritis left ankle, toes and epiphysal end of ribs, chronic subacute verrucose endocarditis of mitral aortic and tricuspid valves. Atheroma of coronaries; chronic bronchitis; emphysema; red atrophy of liver; brown atrophy of heart; acute enlargement and thickening of capsule of spleen; slight interstitial nephritis; hæmorrhoids.

75 (Johnston)—Female, 32. Oct. 10, 1887. Dr. Ross.

ACUTE PERITONITIS and calcification of omentum; chronic endometritis; gallstones; endocarditis; old cicatrices from former ulcerations of colon.

76 (Johnston)—Female, 50. Oct. 10, 1887. Dr. MacDonnell.

CATARRHAL DYSENTERY with follicular ulcers. Healed typhoid ulcers of intestine. Previous typhoid fever, ending in recovery; persistent diarrhœa.

77 (Johnston)—Male, 35. Oct. 14, 1887. Dr. Ross.

CHRONIC PARENCHYMATOUS AND INTERSTITIAL NEPHRITIS. Chronic tuberculosis of lungs, with cavity; Œdema of glottis and right lung; incipient tuberculosis of ileum; anasarca; ascites.

78 (Johnston)—Male, 7. Oct. 14, 1887. Dr. Ross.

NASOPHARYNGEAL DIPHTHERIA.

79 (Johnston)—Male, 35. Oct. 24, 1887.

LEFT EMPYÆMA, with chronic adhesive pleuritis. Right localized pleurisy, with effusion; perforation of sternum by empyæma; tuberculous ulceration of colon; miliary tuberculosis of lungs, liver and kidneys; amyloid spleen; putrid peritonitis.

80 (Johnston)—Female, 27. Nov. 1, 1887.

ACUTE ARSENICAL POISONING: Rough on Rats; death in 7 hours. Chronic mitral endocarditis; chronic (syphilitic?) lymphomata of intestines; gallstones.

81 (Johnston)—Male, 30. Nov. 5, 1887. Dr. Shepherd.

ACUTE TUBERCULOUS MENINGITIS. Nephrotomy; tuberculous cystitis; right tuberculous pyonephrosis; tuberculous vesico rectal perineal fistula; tuberculous peritonitis; miliary tubercles in lungs, liver and kidneys; amyloid liver, spleen and kidneys.

82 (Johnston)—Male, 38. Nov. 10, 1887. Dr. MacDonnell.

CHROIC PULMONARY PHTHISIS; CAVITIES IN BOTH LUNGS. Miliary tuberculosis of right lung, with emphysema; acute and chronic tuberculous pleurisy; amyloid spleen, liver, intestines and kidneys; tuberculous ulceration of ileum, colon and rectum; submucous cyst of bladder; angioma of liver

83 (Lafleur)—Male, 26. Nov. 30, 1887. Dr. Wilkins.

CATARRHAL ULCERATIVE COLITIS.

84 (Johnston)—Male, 55. Dec. 1, 1887. Dr. Ross.

CHRONIC AORTIC ENDOCARDITIS WITH INCOMPETENCY. Dilatation and hypertrophy of both sides of heart; universal adhesive pericarditis; brown induration of lungs; cyanotic induration of kidneys; nutmeg liver; calcification of mesenteric glands and one solitary follicle; hydrothorax; œdema.

85 (Johnston)—Female, 10. Dec. 3, 1887. Dr. Ross.

PHARYNGEAL DIPHTHERIA. Parenchymatous degeneration of heart; acute parenchymatous nephritis.

86 (Johnston)—Male, 23. Dec. 5, 1887. Dr. Roddick.

SEPTIC PNEUMONIA. PHLEGMON AND CARBUNCLE of right side of lip and face; multiple pyæmic infarcts of lung; acute swelling of spleen; acute parenchymatous nephritis.

87 (Johnston)—Male, 60. (Private).

RUPTURE OF LEFT VENTRICLE INTO PERICARDIUM. Fatty infiltration of heart; thrombosis of left anterior coronary artery; cyanotic induration of spleen and kidneys; varicose veins of leg.

88 (Johnston)—Female, 38. Dec. 9, 1887. Dr. Molson.

ACUTE PURULENT MENINGITIS. Puerperal state; acute parenchymatous and chronic interstitial nephritis; acute swelling of spleen; acute and chronic purulent otitis media; thrombus right lateral sinus; gallstone impacted in cystic duct.

89 (Johnston)—Male, 56. Dec. 12, 1887.

FRACTURE OF SKULL. Traumatic softening and hæmorrhage of brain; pulmonary apoplexy; angioma of liver; concretion of prostate.

90 (Johnston)—Male, 50. Dec. 14, 1887.

EARLY GRAY HEPATIZATION OF LEFT LUNG. Acute purulent localized peritonitis left flank and pelvis; catarrhal colitis; acute parenchymatous nephritis, hepatitis and myocarditis; atrophy of left ascending frontal convolution.

91 (Johnston)—Male. Dec. 20, 1887.

ACUTE BRONCHITIS. Hyperæmia of lungs; chronic endocarditis; infarction of spleen. Found dead; suspected opium poisoning.

92 (Johnston)—Female, 3. Dec. 22, 1887. Dr. Major.

DIPHTHERIA of pharynx, larynx and trachea. Atelectasis; broncho-pneumonia; slaty pigmentation of intestinal follicles.

93 (Johnston)—Female, 38. Dec. 23, 1887. Dr. Ross.

TUBERCULOSIS, chronic ulcerative, both lungs; tuberculous meningitis; tuberculous ulceration of intestines; amyloid spleen and intestines.

94 (Johnston)—Male, 4. Dec. 24, 1887. Dr. Buller.

DIPHTHERIA of pharynx, larynx and trachea; tracheotomy; acute vesicular and interstitial emphysema; supernumerary spleen.

95 (Johnston)—Female, 3. Dec. 24, 1887.

DIPHTHERIA of larynx and trachea; acute broncho-pneumonia; accessory spleen.

1888

1 (Johnston)—Male, 30, Jan. 4th, 1888. Dr. Molson.

PULMONARY PHTHISIS. Right tuberculous pleurisy with effusion; miliary tuberculosis of spleen, liver and kidneys; tuberculous peri-hepatitis and peritonitis; acute tuberculous meningitis; chronic suppurative otitis media.

2 (Johnston)—Male. Private case. Jan. 6, 1888. Dr. Armstrong.

HÆMORRHAGE OF RIGHT CORPUS STRIATUM. Heart and kidneys normal

3 (Johnston)—Male. Private case. Jan. 6, 1888. Dr. Armstrong.

THROMBOTIC SOFTENING of left internal capsule. Gumma in third left frontal convolution; descending sclerosis of spinal cord.

4 (Johnston)—Private case. Jan. 12, 1888. Dr. Howard.

MEMBRANOUS LARYNGITIS and tracheitis. Beneath this mucosa appears to be intact; sudden death after intubation.

5 (Johnston)—Male 40. Jan. 12, 1888. Dr. Ross.

MILIARY TUBERCULOSIS. Chronic tuberculous caries lumbar vertebræ; acute miliary tuberculosis of lungs kidneys and liver; fatty liver, chronic hyperplasia of spleen; Calcareous and cystic degeneration of choroid plexus; Descending sclerosis of spinal cord: tuberculous ulcer of larynx with adherent slough.

6 (Johnston)—Private case. Jan. 21, 1888. Drs. Schmidt and Buller.

ACUTE HÆMORRHAGIC pachy- and leptomeningitis. Abscess of frontal sinus, following mucous cyst; purulent abscess of left frontal lobe, acute cerebritis of left frontal lobe; chronic atrophic rhinitis.

7 (Johnston)—Male, 67. Jan. 23, 1888. Dr. Shepherd.

ACUTE PYELONEPHROSIS. Acute Parenchymatous; hydronephrosis; dilated ureters; hypertrophy of middle lobe of prostate.

8 (Johnston)—Male, 68. Jan. 26, 1888. Dr. Ross.

ACUTE LOBAR PNEUMONIA, right upper lobe. Acute bronchitis; acute right pleurisy, adhesions both sides; slight cirrhosis of liver and kidneys; spleen small.

9 (Johnston)—Male, 65, Jan. 28, 1888.

SOFTENING OF BRAIN, with sclerosis; broncho-pneumonia; fœtid bronchitis; granular condition of fourth ventricle; ependymitis; softening in pons.

10. (Johnston)—Male, 40. Jan. 29, 1888.

ACUTE LOBAR PNEUMONIA right upper lobe. Acute pleurisy; slight granular kidneys.

11 (Johnston)—Male, 18. Jan. 30, 1888. Dr. Roddick.

TUBERCULOSIS CARIES OF DORSAL and lumbar vertebræ. Double psoas abscess; acute left pleurisy; chronic adhesive right pleurisy, non-tuberculous; acute swelling of spleen; slaty pigmentation of follicles of intestines.

12 (Johnston)—Male, 4 hours. Jan. 30, 1888. Dr. J. C. Cameron.

HÆMORRHAGE OF longitudinal sinus. Atelectasis of lungs.

13 (Johnston)—Male, 34. Feb. 8, 1888. Dr. Ross.

CANCEROUS ULCER OF STOMACH, invading left lobe of liver. Amyloid spleen, intestines and liver.

14 (Johnston)—Male, 24. Feb. 9, 1888. Dr. Bell.

AMPUTATION OF left femur sloughing of stump. Secondary hæmorrhage; artery sloughed through at point of ligation; pyæmic abscess in left pectoral region; fibrous anchylosis left hip; anæmia of organs.

15 (Johnston)—Male, 6. Feb. 10, 1888. Dr. Ross.

DIPHTHERIA of pharynx, larynx and trachea; broncho-pneumonia; intubation.

16 (Johnston)—Female, 40. Feb. 13, 1888. Drs. Molson and Stewart.

EXOPHTHALMIC GOITRE thrombosis of left vertebral and inferior cerebellar arteries, Hæmorrhagic cyst in pons (hæmatoma) slight chronic aortic endocarditis; infarction of spleen; cystic bronchocele.

17 (Johnston)—Female, 25. Feb. 15, 1888. Dr. Molson.

SUBACUTE TUBERCULOUS MENINGITIS. Slight acute broncho-pneumonia; chronic adhesive pleurisy; gestation.

18 (Johnston)—Female. Feb. 17, 1888.

ACUTE AORTIC AND MITRAL ENDOCARDITIS. Nutmeg liver; anasarca; acute parenchymatous myocarditis.

19 (Johnston)—Female, 21. Feb. 17, 1888.

VALVULAR HEART DISEASE. Dilatation of right ventricle; emphysema; nutmeg liver; hyperæmia of intestines; anasarca; hydrothorax; ascites; chronic adhesive perimetritis.

20 (Johnston)—Female, 20. Feb. 25, 1888. Dr. Ross.

PERFORATION OF ULCER OF STOMACH; general acute peritonitis; two other ulcers of stomach; gestation third month.

21 (Johnston)—Male, 20. Feb. 24, 1888. Dr. Bell.

PYÆMIA. Sutured right patella; abscess and phlegmon right leg; acute purulent arthritis right ankle and knee; acute verrucose infectious endocarditis; miliary abscess of heart; infarction of spleen, kidneys and left corpus striatum; cyst size of walnut in right lobe of liver; superficial ulcer of right shin.

22 (Johnston)—Male, 43. Feb. 25, 1888. Dr. Ross.

ACUTE LOBAR PNEUMONIA right upper lobe. Gummatous hepatitis, old.

23 (Johnston)—Male, Feb. 28, 1888.

ANEURYSM OF ABDOMINAL AORTA. Erosion of the body of the 3rd lumbar vertebra; dilatation of heart; atheroma of aorta; general arterio sclerosis; slight interstitial nephritis; chronic bronchitis; slight œdema of lungs.

24 (Lafleur)—Male, 1½. Feb. 28, 1888. Dr. Molson.

DIPHTHERIA OF PHARYNX, larynx and trachea. Tracheotomy; interstitial emphysema; atelectasis; broncho-pneumonia.

25 (Johnston)—Male, 60. Feb. 28, 1888. Dr. Roddick.

Railroad accident. FRACTURE OF RIBS, 7 to 11 right; laceration of pleura and right lung; traumatic pneumonia; bronchopneumonia; slight hæmorrhage into cerebral ventricles.

26 (Johnston)—Female, 45. March 2, 1888. Dr. Ross.

CHRONIC PARENCHYMATOUS NEPHRITIS. Chronic mitral and tricuspid endocarditis; cirrhotic and nutmeg liver; hæmorrhages of spleen; acute gastro-enteritis; hypertrophic endometritis.

27 (Johnston)—Male, 60. March 5, 1888. Dr. Ross.

PULMONARY PHTHISIS. Cavity in right lung; emphysema left lung; acute miliary tuberculosis both lungs; right tuberculous adhesive pleurisy; tuberculous ulcer of larynx; tuberculous enteritis; fatty liver; miliary tuberculosis of kidneys and spleen.

28 (Johnston)—[illegible], 80. March 5, 1888.

INOCULITION TUBERCULOSIS of subcutaneous tissue and muscles of left arm; of axillary glands; extension to left lung; brown atrophy of heart; atheroma of valves; chronic hypertrophic catarrhal colitis with polypi; polypoid gastritis; annular ulcer of pylorus.

29 (Johnston)—Female, 4. March 5, 1888. Dr. Ross.

DIPHTHERIA nose, pharynx and larynx (hæmorrhagic), old infarct of lung; acute hæmorrhagic broncho-pneumonia; infarct of spleen; emphysema of peritoneum; epi and endocardial ecchymoses; chronic mitral and aortic endocarditis.

30 (Johnston)—Female, 7. March 7, 1888.

DIPHTHERIA of pharynx, larynx and trachea. Acute inflation of lungs; Broncho-pneumonia; cloudy swelling of kidneys; follicular enteritis; ascarides.

31 (Johnston)—Female, 5. March, 7, 1888. Dr. Ross.

DIPHTHERIA of pharynx, larynx and trachea atelectasis; broncho-pneumonia; cloudy swelling of kidneys.

32 (Johnston)—Male, 50. March 12, 1888. Dr. Molson.

PNEUMONIA. Late red hepatization upper and middle lobe right lung; acute right pleurisy (fibrinous); acute bronchitis; cloudy swelling of kidneys and heart.

33 (Johnston)—Male, 25. March 12, 1888. Dr. Molson.

No organic disease found to account for death.

34 (Lafleur)—Male, 43. April 2, 1888. Dr. Bell.

FRACTURE OF RIGHT LEG. Syncope.

35 (Lafleur)—Male, 40. April 9, 1888. Dr. Molson.

PHTHISIS BOTH LUNGS. Tuberculous meningitis.

36 (Lafleur)—Male, 67. April 10, 1888. Dr. Bell.

GENERAL TUBERCULOSIS. Right tuberculous pyelitis.

37 (Lafleur)—Male, 65. April 10, 1888. Dr. Shepherd.

PNEUMONIA base of right lung, commencing pneumonia right upper lobe; pyelonephritis purulent; chronic cystitis; enlarged prostate; infiltration of urine with gangrene of scrotum and perineum.

38 (Lafleur)—Male, 21. April 12, 1888. Dr. MacDonnell.

POTASSIUM BICHROMATE POISONING. Acute gastro enteritis; methæmoglobinuria.

39 (Lafleur)—Male, 44. April 15, 1888. Dr. Bell.

SUPPURATIVE APPENDICITIS (chronic) with sinuses. Commencing perforative septic peritonitis; abscesses of liver; sero-fibrinous pericarditis; slight fatty kidney.

40 (Lafleur)—Female, 75. April 23, 1888.

CIRRHOSIS OF LIVER AND KIDNEYS, MULTILOCULAR CYST RIGHT OVARY. Cystic change of left ovary; fibromyoma uteri; senile atrophy of heart.

41 Not entered.

42 (Lafleur)—Male, 47. April 27. Dr. MacDonnell.

PNEUMONIA lower lobe both lungs; commencing pneumonia left upper lobe and right upper lobe; chronic parenchymatous nephritis: spleen firm 620 grams.

43. (Lafleur)—Male, 61. May 7, 1888. Dr. Bell.

ALVEOLAR SARCOMA of 9th and 10th dorsal vertebræ. Secondary in liver; broncho-pneumonia right upper lobe; gray hepatization right lower lobe; chronic interstitial nephritis; bedsore.

44 to 46 Not entered.

47 (Lafleur)—Male, 35. May 26, 1888. Dr. Macdonnell.

ACUTE TUBERCULOSIS with left lung; acute tuberculosis right lung; tuberculous ulcers throughout intestines; fatty liver.

48 Female, 60. May 26, 1888.

Not entered.

49 (Lafleur)—Female, 27. May 30, 1888. Dr. Wilkins.

TUBERCULOSIS with cavities; polypus fundus uteri at placental site; tuberculous ulcers of intestine and rectum; localized adhesive peritonitis.

50 Not entered.

51 (Lafleur)—Female, 29. June 1, 1888. Dr. Wilkins.

CHRONIC PARENCHYMATOUS NEPHRITIS. Slight interstitial nephritis; diphtheritic ulcerative colitis; right hydrothorax; chronic adhesive peritonitis; right pyosalpinx; chronic enlargement of spleen; gumma of spleen; warty excrescences of descending arch of aorta.

52 (Lafleur)—Male, 37. June 2, 1888. Dr. Shepherd.

TUBERCULOUS ULCER OF TONGUE. Removal of tongue; acute general miliary tuberculosis.

53-54 Not entered.

55 (Lafleur)—Male, 5. June 21, 1888.

DIPHTHERIA of nose, pharynx and larynx. Broncho-pneumonia; ateleclasis.

56 (Lafleur)—Male, 32. June 27, 1888. Dr. MacDonnell.

PYÆMIA. Subpectoral abscesses; purulent arthritis; abscess of right lung.

57 (Lafleur)—Male, 10. June 28, 1888.

SCLEROTIC AND VERRUCOSE mitral endocarditis. Chronic interstitial nephritis; dilatation and hypertrophy of heart; nutmeg liver; œdema of lungs; double hydrothorax; hydropericardium; ecchymoses of bladder; anasarca.

58 (Lafleur)—Male, 70. June 28, 1888. Dr. MacDonnell.

FATTY AND CIRRHOTIC LIVER. Fatty degeneration and fat infiltration of heart; icterus; œdema of lungs; muco-purulent bronchitis; contracted granular kidneys; right inguinal hernia.

59 Not entered.

60 (Lafleur)—Male, 72. July 30, 1888. Dr. Shepherd.

STRANGULATED HERNIA. Radical operation; constriction of eight inches of intestine; acute lobar pneumonia; purulent bronchitis; caseous nodules apex and bronchial glands.

61-62 Notes not entered.

63 (Lafleur)—Female, 60. Aug. 4, 1888. Dr. Wilkins.

MULTIPLE PURPURIC ECCHYMOSES of skin, kidneys, bladder, stomach, intestines, pleura and pericardium; broncho-pneumonia; moma uteri.

64 (Lafleur)—Male, 32. Sept. 10, 1888. Dr. Roddick.

SUICIDE. Two bullet wounds left auditory canal; fracture left petrous bone; acute purulent meningitis; broncho-pneumonia.

65 (Lafleur)—Female. Sept. 18, 1888. Dr. Wilkins.

SYPHILIS. Gumma of lung and liver; ulceration of intestine; amyloid liver, spleen and kidneys.

66 (Lafleur)—Male, Sept. Dr. Wilkins.

ACUTE RIGHT LOBAR PNEUMONIA. Commencing pneumonia left base; gangrene of right lung; purulent thrombus cerebral sinuses; and veins of Galen; superficial encephalitis; hæmorrhagic spots in corpus callosum; middle ear normal.

67 (Lafleur)—Male, 16. Sept. 18, 1888. Dr. Wilkins.

TYPHOID FEVER ulceration of intestines.

68 (Lafleur)—Male, 79. Sept. 28, 1888. Dr. MacDonnell.

HYPERTROPHY and dilatation of heart; fatty degeneration. Hydrothorax; œdema of lungs; anasarca; cyanotic induration of kidneys; fatty liver; old scar on prepuce; slight double hernia; external hœmorrhoides.

69 (Lafleur)—Female, 47. Sept. 21, 1888. Dr. Roddick.

CARCINOMA OF RECTUM. Secondary in inguinal glands and liver; chronic bronchitis.

70 (Lafleur)—Male, one week. Sept. 24, 1888. Maternity.

CAPILLARY BRONCHITIS. Asphyxia; froth in trachea; aspiration of food.

71 (Lafleur)—Male, 60. Sept. 29, 1888.

CEREBRAL HÆMORRHAGE left corpus striatum; arterio-sclerosis; slight interstitial nephritis; slight hypertrophy of left ventricle.

72 (Lafleur)—Male, 19. Oct. 5, 1888. Dr. Ross.

APPENDICITIS. Perforation; acute general purulent peritonitis; cloudy swelling of heart muscle.

73 to 77 Not entered.

78 (Lafleur)—Male, 17. Nov. 10, 1888. Dr. Molson.

PHITHISIS. Cavities both lungs; anæmia; fatty liver and kidneys; brown-atrophy of heart; tuberculous enteritis; miliary tubercles in suprarenals.

79 (Lafleur)—Male, 52. Nov. 16, 1888. Dr. Bell.

CHRONIC ABSCESS OF PANCREAS. Obstructive jaundice; sero-fibrinous peritonitis; acute fibrinous pericarditis; calcified nodule lower lobe right lung; brown-atrophy of heart; sclerosis of valves; abscess of tip of vermiform appendix.

80 to 82 Not entered.

83 (Lafleur)—Female, 30. Nov. 30, 1888. Dr. Gardner.

ACUTE RIGHT lobar pneumonia. Subinvolution of uterus; parenchymatous myocarditis, slight fatty kidney; slight muco enteritis.

84 (Lafleur)—Female, 55, Dec. 6, 1888. Dr. Ross.

ACUTE LOBAR PNEUNONIA right upper lobe; acute diphtheritic enterocolitis; chronic cervical endometritis; fatty heart.

85 Not entered.

86 (Lafleur)—Female, 23. Dec. 12, 1888. Dr. Ross.

PHARYNGEAL DIPHTHERIA. Broncho pneumonia.

87 Not entered.

88 (Lafleur)—Male, 65. Dec. 20, 1888. Dr. Ross.

ACUTE FIBRINO purulent peritonitis. Cause not apparent: Sclerosis aortic valves; calcification; fibroid nodule left apex.

89-90 Not entered.

1889

1 (Lafleur)—Female, 50. Jan. 11, 1889. Dr. Ross.

CEREBRAL SOFTENING OF BOTH CRURA (thrombotic ?). Slight chronic interstitial nephritis; arterio-sclerosis; catarrhal enteritis; chronic adhesive pelvic peritonitis; brown atrophy of liver; caseous nodule in left lung; polypus of cervix uteri.

2 (Lafleur)—Male, 23. Jan. 25, 1889. Dr. Ross.

ACUTE SUPPURATIVE NEPHRITIS. Acute hæmorrhagic cystitis; acute enlargement of spleen; acute bronchitis.

3 (Lafleur)—Female, 35. Jan. 29, 1889.

TUBERCULOUS PERITONITIS. Acute miliary tuberculosis; bedsores; eczema about genitals.

4 (Lafleur)—Female, 17. Feb. 25, 1889.

VALVULAR HEART DISEASE.—Mitral sclerosis; dilatation and hypertrophy of heart; icterus; ascites; bedsore.

5 (Finley)—Female, 42. April 5, 1889. Dr. Wilkins.

CIRRHOSIS OF KIDNEY. Alcoholism; fatty and cirrhotic liver; fatty degeneration of heart; atheroma of aorta; ascites; anasarca; œdema of pia; encapsuled trichinosis of muscle (old).

6 (Finley)—Female, 40. April 14, 1889. Dr. Wilkins.

ULCER OF STOMACH with open artery in base. Fatty and cirrhotic liver alcoholism; cirrhotic kidneys; hæmorrhage in stomach and intestine; fatty degeneration of heart; ossifying pachymengitis; gall stones.

7 (Finley)—Female, 42. April 22, 1889. Dr. Stewart.

PUERPERAL SEPTICÆMIA. Purulent parametritis; abscess in both broad ligaments: no peritonitis; acute enlargement of spleen with infarct; slight interstitial nephritis; cloudy swelling of kidneys and liver; pyæmic abscesses in pectoral muscles.

8 (Finley)—Female, 40. April 30, 1889.

CARBOLIC ACID POISONING. Quantity unknown; 48 hours duration; punctiform hæmorrhages of stomach; commencing parenchymatous nephritis.

9 (Finley)—Female, 52. April 30, 1889. Dr. Roddick.

CANCER OF ASCENDING COLON infiltrating abdominal wall; lacing lobe of liver; thrombosis of iliac veins; acute purulent bronchitis; right broncho-pneumonia; acute right pleurisy.

10 (Finley)—Female, 55. April 30, 1889.

ACUTE LOBAR PNEUMONIA (left). Slight interstitial nephritis; hypertrophy of heart: lacing lobe of liver; œdema of glottis.

11 (Finley)– Male, 52. April 30. Drs. Ross and Shepherd.

ADENO CARCINOMA of sigmoid flexure with external and vesical fistulæ; secondary cancer of liver and retroperitoneal glands; old tuberculous pyelonephritis (right); caseous nodules in lungs.

12 Not entered.

13 (Finley)—Male, 45. May 8, 1889. (Coroner's case).

RUPTURE OF ILEUM. Bruising of abdomen; general peritonitis.

14 (Finley)—Female, 24. May 9, 1889. Dr. Sutherland.

PYÆMIA. Retropharyngeal abscess; thrombosis internal jugular and lateral sinus: abscess of dura mater; collapse of lungs; sclerosis mitral valve; cloudy swelling of liver and kidneys; acute enlargement of spleen; parovarian cysts; hydrosalpinx.

15 (Finley)—Female, 46. May 12, 1889. Dr. Stewart.

CANCER OF PYLORUS infiltrating colon; secondary in liver: fusion of pulmonary valves; aortic endocarditis with incompetence; angioma of liver; caseous nodules in apices.

16 (Finley)—Female, 19. May 26, 1889. Dr. Wilkins.

GENERAL PURULENT PERITONITIS. Extreme cirrhosis of kidneys; acute plastic pleurisy; hydrosalpinx; caseous nodules of lungs.

17 (Finley)—Male, 22. June 2, 1889. Dr. Stewart.

CHRONIC PHTHISIS WITH CAVITIES. Tuberculous enteritis; early tubercle of larynx; catarrhal gastritis; p.m. digestion and perforation of œsophagus.

18 (Finley)—Female, 18. June 2, 1889. Dr. Shepherd.

STRANGULATED INGUINAL HERNIA. No gangrene or peritonitis.

19 (Finley)—Male, 20. June 5, 1889. Dr. Stewart.

ACUTE PARENCHYMATOUS NEPHRITIS. Acute glomerulonephritis; hypertrophy and dilatation of heart; commencing atheroma of aorta; œdema of lungs; hyperæmia of intestines.

20 (Finley)—Male, 61. June 5, 1889. Dr. Stewart.

CIRRHOSIS OF STOMACH with ulceration. Cirrhotic kidneys; gall stones; tabes dorsalis.

21 (Finlay)—Male, 40. June 9, 1889. Dr. Stewart.

MULTIPLE LYMPHOSARCOMA? of pleura and peritoneum; sub acute pleurisy and pericarditis with effusion; tuberculosis?

22 (Finley)—Female, 36. May 14, 1889. Dr. Wilkins.

CHRONIC ULCERATIVE COLITIS. Fatty liver; chronic adhesive peritonitis.

23 (Finley)—Male, 66. June 10, 1889. Dr. Wilkins.

GENERAL ARTERIOSCLEROSIS. Occlusion of ventricles of brain; miliary aneurysms; obliterative endarteritis; hypertrophy and dilatation of left heart; sclerosis of valves; atrophy of liver; dilatation of stomach; kidneys normal.

24 (Finley)—Male, 1½. June 20, 1889. Dr. Burland.

PERFORATIVE APPENDICITIS. Fæcal concretions in appendix; acute septic peritonitis.

25 (Finley)—Male, 47. June 24, 1889. Dr. Stewart.

ANGIOSARCOMA RIGHT CRUS CEREBRI.

26 (Finley)—Male, 25. June 24, 1889. Dr. Wilkins.

TYPHOID FEVER. Ulceration of intestines; perforation; commencing general peritonitis; acute enlargement of spleen.

27 (Finley)—Female, 21. June 25. Dr. Wilkins and Shepherd.

RIGHT EMPYEMA. Thoracocentesis; collapse of lung; recent and old pleurisy; fatty liver.

28 (Finley) Male, 27. June 27, 1889.

VALVULAR DISEASE OF HEART. Aortic incompetence; old and recent aortic endocarditis; slight sclerosis of mitral value; universal synechiæ of pericardium; hypertrophy and dilatation of heart; œdema of lungs; spleen large and firm.

29 (Finley)—Male, 26. July 2, 1889. Dr. Stewart.

SUNSTROKE. Alcoholism; fluidity of blood, well marked rigidity in lower extremities; absent in upper 17 hours p.m. Granular and fatty degeneration with acute dilatation of both auricular and ventricular orifices; Punctiform hæmorrhages beneath epicardium; œdema and hyperæmia of lungs; enlargement of solitary follicles throughout intestines; early decomposition of organs.

30 (Finley)—Male, 50. July 9, 1889. Dr. Bell.

SCIRRHUS ADENOCARCINOMA of hepatic flexure of colon, with stricture; trichinosis; fatty liver with secondary cancer.

31 (Finley)—Female, 34. July 10, 1889. Dr. Stewart.

ACUTE PARENCHYMATOUS NEPHRITIS. Pregnancy; fatty liver; catarrhal ulcers of colon.

32 (Finley)—Male, 55. Aug. 9, 1889. Dr. Wilkins.

TYPHOID FEVER. Ulceration of intestines (3rd week); parenchymatous degeneration of heart and liver; acute enlargement of spleen; small cavity at each apex; ununited fracture right external condyle; bullet embedded in frontal bone.

33 (Finley)—Female, 17. Aug. 13, 1889. Dr. MacDonnell.

TYPHOID FEVER. Ulceration of ileum and large intestine; large soft spleen; granular degeneration of liver and kidneys; œdema of lungs; slight chronic endocarditis of tricuspid and mitral valves.

34 (Finley)—Female, 34. Aug. 13, 1889. Dr. Stewart.

CASEOUS PNEUMONIA; left lung cavites at apex; œdema and caseous pneumonia right lung; universal pleural synechiæ; amyloid spleen liver and kidneys without enlargement; amyloid intestines.

35 (Finley) Male, 51. Aug. 23, 1889. Dr. MacDonnell.

ATROPHIC CIRRHOSIS OF LIVER. Jaundice; granular and fatty degeneration of heart; commencing atheroma of aortic valves; dilatation of both ventricles and auricular orifices; right hydrothorax; recent infarct of lung; old infarct of spleen and right kidney; gastro-intestinal catarrh; prostatic calculi; syphilitic ulceration and scarring of legs.

36 (Finley)—Male, 36. Aug. 27, 1889. Dr. Fenwick.

ABSCESS OF LIVER. Dysenteric ulceration of large intestine: broncho-pneumonia.

37 (Finley)—Female, 56. Sept. 4, 1889. Dr. MacDonnell.

ACUTE CATARRHAL ENTEROCOLITIS. Dilatation of stomach; brown atrophy of liver; pleural adhesions; calcified apical nodules; calcified and caseous bronchial glands; fatty degeneration of heart with slight dilatation of ventricles; no poison found chemically; suspected ptomaine poison; old perihepatic adhesions.

38 (Finley)—Male, 38. Sept. 10, 1889. Dr. Fenwick.

PYÆMIA. Left empyema; right broncho-pneumonia; acute plastic pleurisy; parenchymatous degeneration of liver and spleen; comminuted fracture of left thigh; fatty degeneration of right ventricle; collapse; induration and œdema of left lung.

39 (Finley)—Female, 19. Sept. 10, 1889.

TYPHOID FEVER (14th day). Swelling of Peyer's patches and of solitary follicles of large intestine to within three inches of rectum; cloudy swelling of liver; enlargement of spleen and mesenteric glands; atelectasis and hyperæmia of bases of lungs.

40 (Finley)—Male 25. Dr. Blackader.

ABSCESS OF BRAIN, left temporal lobe; perforation of left squamous bone.

41 (Finley)—Male, 45. Sept. 12, 1889. Dr. Wilkins.

CASEOUS PNEUMONIA. Caseous peribronchitis and cavity left lung; right lung, no cavity; slight tuberculous ulceration of ileum; commencing tuberculosis of larynx.

42 (Finley) Male 23. Sept. 14, 1889.

TYPHOID FEVER (16th day). Enlargement of intestinal follicles with reticular ulceration; enlargement of spleen and mesentric glands.

3 (Finley)—Male, 65. Sept. 15, 1889. Dr. MacDonnell.

VALVULAR HEART DISEASE. Hypertrophy of heart, bilateral; sclerosis of valves; nutmeg liver; ascites hydrothorax; œdema; catarrhal gastritis cyanotic induration of kidneys.

44 (Johnston)—Infant, 3 weeks. Sept. 27, 1889.

MARASMUS. No special change in organs; eczema about buttocks; syphilis?

45 (Williams)—Male, 25 days. Sept. 30, 1889.

MARASMUS. No special change in organs.

46 (Williams)—Male, 1 month. Sept. 28, 1889.

MARASMUS. Rachitis.

47 (Johnston)—Male, 50. Oct. 1, 1889. Dr. MacDonnell.

GOUT; CHRONIC INTERSTITIAL NEPHRITIS. Severe urate deposit in kidneys; extensive uratic arthritis and tenosynovitis throughout the whole body; tophi; follicular abscess of pharynx; enlargement of posterior cervical glands; acute left pleurisy with effusion; ecchymosis of mucosa of stomach; melæna.

48 (Johnston)—Private case. Oct. 4, 1889.

MEDULLARY CANCER OF STOMACH in middle region, greater curvature; secondary cancer of liver.

49 (Johnston)—Male, 35. Oct. 5, 1889.

TYPHOID FEVER. Ulceration of ileum, colon and appendix; a little blood in intestine above valve; slaty pigmentation of Peyer's patches; acute swelling of spleen and mesenteric glands; hyperæmia and partial atelectasis of both lungs at bases; patency of foramen ovale; slight hyaline degeneration of recti abdominales; fatty liver; ecchymoses on surface.

50 (Johnston)—Male, 74. Oct. 14, 1889. Dr. Molson.

INTERSTITIAL NEPHRITIS. Acute and chronic bronchitis; dilatation of heart with fatty degeneration; atheroma; nutmeg liver; chronic adhesive peritonitis; old tuberculosis at apices of lungs.

51 (Johnston)—Male, 27. Oct. 15, 1889. Dr. Roddick.

FRACTURE OF LEFT OS INNOMINATUM. Dislocation of both sacro-iliac articulations; Pott's fracture of left leg; laceration of intestines.

52 Johnston)—Female, 40. Oct. 21, 1889.

ACUTE LEFT LOBAR PNEUMONIA with pleurisy; multiple broncho-pneumonia; large soft spleen; fatty liver.

53 (Johnston)—Male, 28. Oct. 27, 1889. Dr. Molson.

MASTOIDITIS, phlebitis of right lateral sinus and internal jugular. Chronic purulent right otitis media. Acute swelling of spleen with multiple infarcts; accessory spleen; acute parenchymatous nephritis; acute and chronic local peritonitis; anæmia; slight catarrhal enteritis; hyperæmia of lungs with slight pneumonia.

54 (Johnston)—Female, 10. Oct. 29, 1889. Dr. MacDonnell.

ACUTE MENINGITIS (non-tuberculous). Sabacute pachymeningitis, with distension of ventricles; acute pneumothorax from localized necrosing pleuritis of left lung; hæmorrhage into papillary muscles; optic neuritis.

55 (Johnston)—Male, 40. Oct. 31, 1889. Dr. Bell.

FRACTURE OF laminæ of 5th and 6th vertebræ. Laminectomy; partial laceration and hæmorrhage of spinal cord.

56 (Johnston)—Male, 57. Oct. 31, 1889. Dr. MacDonnell.

SCIRRHOUS CANCER OF PYLORUS; secondary cancer of right kidney and posterior mediastinal glands.

57 Female, 45. Nov. 4, 1889. Dr. Molson and Stewart.

DIPHTHERIA of pharynx, larynx, trachea and bronchi. Emphysemia and broncho-pneumonia; acute hæmorrhagic nephritis; myoma uteri.

58 (Johnston)—Male, 27. Nov. 6th, 1889. Dr. MacDonnell.

ACUTE LOBAR PNEUMONIA. Hæmorrhagic infarction of right lung; acute pleurisy; acute croupous tracheitis; parenchymatous nephritis; foreign body in appendix vermiformis.

59 (Johnston)—Private case. Nov. 13, 1889. Dr. Browne.

RUPTURE OF HEART. Hæmorrhage into pericardium; myomalacia cordis; fat infiltration of heart; atheroma of coronaries.

60 (Johnston)—Male, 67. Nov. 14, 1889. Dr. Roddick.

MELANOTIC SARCOMA OF SKIN OF LEFT GROIN. Secondary in inguinal glands; universal adhesive pericarditis; mural thrombus with white softening of right ventricle; grey degeneration of cœliac ganglia; pigmentation of skin of forehead; chronic granular kidneys; thickening of spleen capsule; hyaline thickening of splenic artery; hæmorrhoids; complete fistula in ano.

61 (Johnston)—Female, 27. Nov. 15, 1889. Dr. Molson.

ACUTE MILIARY TUBERCULOSIS. Anæmia; broncho-pneumonia; old apical cavities; enlarged spleen; tuberculosis of bronchial glands.

62 (Johnston)—Female, 63. Nov. 18, 1889.

ATROPHIC CIRRHOSIS OF LIVER. Emphysema; obsolete tuberculosis of apices; brownish rash on legs; pedunculated cyst of right ovary; ascites.

63 (Johnston)—Male, 50. Private case.

CHRONIC INTERSTITIAL NEPHRITIS. Chronic ulcerative catarrhal colitis; enlargement of suprarenal capsules; fibrosis of cœliac plexus.

64 (Johnston)—Female, 22. Nov. 24, 1889.

TYPHOID FEVER (stage of healing with relapse). Multiple follicular ulceration of stomach with hæmorrhagic erosions; acute parenchymatous nephritis; abortion; lactation; suppurative left mastitis; fatty degeneration of intima of aorta; parenchymatous myocarditis; slight laceration of cervix uteri.

65 (Johnston)—Female, 40. Nov. 30, 1889. Dr. MacDonnell.

ACUTE LOBAR PNEUMONIA. Chronic insterstitial pneumonia with organization of the exudate; chalicosis; acute purulent bronchitis; caseous bronchial glands; brown atrophy of heart; slight cloudy swelling of kidneys.

66 (Johnston)—Male, 49. Dec. 1, 1889. Dr. Molson.

ATROPHIC CIRRHOSIS OF LIVER. Acute tuberculous pleurisy and peritonitis; chronic pulmonary tuberculosis; hæmatoma in right iliac fossa (course not established); brown atrophy of heart; atheroma of aorta; cyanotic induration of kidneys; hæmorrhagic infarction of spleen; ulceration of ileum (tuberculous).

67 (Johnston)—Male, 55. Dec. 3, 1889. Dr. MacDonnell.

CANCER OF PYLORUS. Secondary in liver, lymph glands and peritoneum; ascites; chronic hypertrophic cystic gastritis; chronic fœtid bronchitis; broncho pneumonia.

68 (Johnston)—Male, 40. Dec. 7, 1889. Dr. Bell.

COMPOUND FRACTURE of left tibia and fibula. Exostosis of skull cap; osteophytes of dura mater.

69 (Johnston)—Female, 44. Dec. 12, 1889. Dr. MacDonnell.

MULTIPLE THROMBOSIS AND RECURRENT PULMONARY EMBOLISM. Thrombosis of femoral vein; subacute peritonitis; localized right adhesive pleurisy; dilatation of both fallopian tubes; interstitial pancreatitis with cysts; ecchymosis of stomach; end-thrombosis of gastric veins; erythema nodosum; ascites.

70 (Johnston)—Female, 17. Dec. 19, 1889.

MULTIPLE GANGRENE OF RIGHT LUNG. Chronic mitral and acute mitral and aortic endocarditis; universal pericardial synechiæ; hypertrophy and dilatation of both sides of heart; obliterative thrombosis of left internal jugular, vertebral and innominate veins; thrombosis of left femoral vein; embolism of pulmonary arteries; acute bronchitis; acute right pleurisy with effusion; red atrophy of liver; cyanotic induration of kidneys; ascites; anasarca.

71 (Johnston)—Female, 4. Dec. 20, 1889.

DIPHTHERIA of pharynx, larynx, trachea and main bronchi. Hyperæmia of both lungs; slight broncho-pneumonia; cloudy swelling of kidneys; slaty pigmentation of Peyer's patches.

72 (Johnston)—Male, 55. Dec. 21, 1889. Dr. Molson.

Chronic mitral endocarditis; dilatation and hypertrophy both sides of heart; mural thrombi; brown induration with multiple infarcts; double hydrothorax: cyanotic atrophy of liver; chronic interstitial nephritis.

73 (Johnston)—Male, 24. Dec. 23, 1889. Dr. Roddick.

LACERATION OF URETHRA behind bulb. Moderate stricture of urethra; congestion of kidneys? cloudy swelling of liver; ecchymoses of stomach and heart; calcification of bronchial glands; toxæmia. (?)

74 (Johnston)—Male, 55. Dec. 28, 1889. Dr. MacDonnell.

CEREBRAL HÆMORRHAGE (recurrent). Chronic interstitial nephritis; albuminuric retinitis; atrophy of tongue; arterio sclerosis; hypertrophy of heart; chronic mitral endocarditis; old healed tubercles at left apex; acute broncho pneumonia; emphysema; slight brown induration of lungs.

75 (Johnston)—Male. Dr. MacDonnell.

CHRONIC INTERSTITIAL NEPHRITIS. Hypertrophy of heart with dilatation.

1890

1 (Finley)—Male, 55, Jan. 22nd, 1890. Dr. MacDonnell.

ACUTE LOBAR PNEUMONIA, left upper lobe. Hypertrophy and dilatation of heart; chronic aortic endocarditis with fusion of segments; acute endocarditis with small aneurysm of sinus valsalæ and of pars membranosa; slight mitral endocarditis; cyanotic induration of kidnies and spleen infarct of spleen.

2 (Johnston)—Male, 49, Feb. 3rd, 1890. Dr. MacDonnell.

ACUTE LOBAR PNEUMONIA, left base. Acute fibrinous pleurisy; emphysema; acute parenchymatous nephritis and chronic interstitial nephritis; pyelitis and hydronephrosis; chronic purulent prostatitis; brown atrophy of heart; fibrous nodule, free in peritoneum. Nothing abnormal in pancreas or brain.

3 (Johnston)—Female, 60, Feb. 2nd, 1890. Private case.

CHRONIC MITRAL ENDOCARDITIS, with stenosis. Dilatation and hypertrophy of heart; slight interstitial nephritis; ascites; hydrothorax.

4 (Johnston)—Male, 44, Feb. 6th, 1890. Dr. MacDonnell.

ANEURYISM OF TRANSVERSE ARCH OF AORTA. Moderate compression of trachea; hyperæmia of lungs; cyst in wall of gall bladder; phlebotomy.

5 (Johnston)—Male, 33. Dr. Bell.

STRICTURE OF URETHRA; chronic cystritis; prostatitis; pyelonephritis; emphysema of lungs; thickening of capsule of spleen.

6 (Johnston)—Male.

CHRONIC SUPPURATIVE TUBERCULOUS URETHRITIS. Diphtheritic hæmorrhagic cystitis; multiple chronic interstitial nephritis; obsolete apical tuberculosis; chronic interstitial pneumonia right lung; brown atrophy of heart and liver; bed sores.

7 (Johnston)—Female, 25, Feb. 8th, 1890. Dr. MacDonnell.

INFLUENZA. Multiple Miliary Hæmorrhages of white substance of brain, especially in internal capsule; bronchopneumonia; acute glomerulo nephritis.

8 (Johnston)—Male, 37, Feb. 8th, 1890. Dr. Bell.

DOUBLE HERNIA. Radical operation. Slaty pigmentation of peritoneum in iliac regions; bronchopneumonia; slight fatty liver; cyst in left corpus callosum (lymphatic cyst).

9 (Johnston)—Male, 23, Feb. 10th, 1890.

ACUTE TUBERCULOUS MENINGITIS. Chronic pulmonary tuberculosis; excision of left testicle (for tubercle); atrophy of left seminal vesicle; chronic abcess in right kidney and left pectoral region; calcification in tonsils.

10 (Johnston)—Male, 50, Feb. 10th, 1890. Dr. MacDonnell.

CEREBRAL HÆMORRHAGE ANEURYSM; rupture of angioma of liver; slight interstitial nephritis arteriosclerosis; hypertrophy of heart.

11 (Johnston)—Male, 34, Feb. 19th, 1890. Dr. MacDonnell.

ANEURYSM OF ARCH. Rupture into posterior mediastinum, with formation of false aneurysm, which ruptured into stomach; hæmorrhage into sheath of vagus nerve; recent and old infarcts of lungs; enlargement of spleen; blood clot in stomach and duodenum.

12 (Johnston)—Feb. 20th, 1890.

CHRONIC PHTHISIS with cavities (both lungs); caseous pneumonia; universal adhesive pleurisy.

13 (Johnston)—60. Private case.

PYÆMIC ABSCESSES in great omentum, mesorectum and gastro hepatic omentum; abscesses in spleen; thrombi in both iliac veins; pneumonia.

14 (Johnston)—Female, 50, Feb. 28th, 1890. Dr. Molson.

PULMONARY EMBOLISM AND MULTIPLE GANGRENE OF LUNG. Right pleurisy with effusion; nutmeg liver; myoma uteri; anomaly of renal vessels, branch of renal artery given off from aorta, a bifurcation, hypertrophy and dilatation of heart.

15 (Johnston)—Male, 19, March 2nd, 1890. Dr. Bell.

ULCERATIVE MALIGNANT ENDOCARDITIS of mitral and aortic valves; miliary embolic suppurative nephitis; acute septic miliary infarcts of spleen; stricture of urethra; fistula in perineo; hyperœmia and atelectasis base of right lung; chronic adhesive local peritonitis and pleuritis without œdema of arachnoid; streptococcus infection.

16 (Johnston)—Male, 22, March 4th, 1890. Dr. MacDonnell.

ACUTE DOUBLE PLEURISY. PHLEGMON of deep cervical fascia and mediastinum; acute pericarditis; chronic enlargement of spleen; cloudy swelling of kidneys; chronic local peritonitis; caseation and calcification of bronchial glands.

17 (Johnston)—Male, 28, March 7th, 1890.

ACUTE MENINGITIS. Right purulent otitis media; gonorrhœa; caseation of bronchial glands; hyaline appearance of kidneys without amyloid reaction.

18 (Johnston)—Female, 42, March 10th, 1890. Dr. Bell.

BALL THROMBUS L. AURICLE, CHRONIC MITRAL ENDOCARDITIS, with stenosis; dilatation of left auricle, embolism and secondary thrombosis of iliac arteries; gangrene of left foot and leg; acute synovitis of left knee; nutmeg liver; brown induration of lungs; infarcts of kidneys and spleen; hydrothorax.

19 (Johnston)—Private case.

SUPPURATIVE CHOLECYSTITIS, with perforation; gall stones; chronic adhesive peritonitis and acute general purulent peritonitis; bronchopneumonia.

20 (Johnston)—Male, 32, March 21st, 1890.

COLLOID CANCER OF BLADDER. Secondary in pelvic glands; cystotomy operation; double hydronephrosis; anasarca hydrothorax; hydropericardium œdema of lungs; bronchopneumonia; hypertrophy of heart with dilatation; fatty degeneration of heart.

21 (Johnston)—Male, 54, March 24th, 1890. Dr. MacDonnell.

ACUTE LOBAR PNEUMONIA right lower and middle lobes. Chronic interstitial pneumonia; chronic adhesive pleurisy and acute fibrinous pleurisy; hypertrophy of heart; hypertrophy and cirrhosis of kidneys.

22 (Johnston)—Female, 20, March 31st, 1890. Private.

CHRONIC ULCER OF STOMACH. Perforation; acute peritonitis; anæmia.

23 (Johnston)—Female, 62. Dr. Molson.

CANCER OF STOMACH AT FUNDUS. Secondary in portal glands; perisplenitic abscess; acute peritonitis; bronchopneumonia; brown atrophy of heart; arteriosclerosis nodosa.

24 (Johnston)—Female, 14, March 31st, 1890. Dr. Bell.

RETROPHARYNGEAL AND RETROŒSOPHAGEAL CASEOUS TUBERCULOUS ABSCESS. Œdema and emphysema about neck; acute right pleurisy; acute (tuberculous?) peritonitis; infiltration of sheaths of pneumogastric nerves; no caries of cervical vertebræ; constriction of œsophagus.

25 (Johnston)—Male, 55, April 10th, 1890. Dr. Ross.

ANEURYSM OF AORTA in ascending arch. General arteriosclerosis of aortic valve; dilatation and hypertrophy with fatty degeneration of heart; chronic adhesive pleurisy; interstitial pneumonia; calcified bronchial glands; chronic enlargement of spleen; cyanotic induration of kidneys and liver; Liebermeister's furrows; angioma of liver.

26 (Johnston)—Male, 61, April 10th, 1890. Dr. Fenwick.

SUICIDE, by revolver wound of brain. Fracture of right orbital plate, right lachrymal and nasal bones; suppuration in track of wound; abscess in right antrum of Highmore; chronic hypertrophic rhinitis; laceration of anterior frontal region, right side; acute septic meningitis.

27 (Johnston)—Female, 3½.

ACUTE BRONCHO-PNEUMONIA. Catarrhal laryngitis.

28 (Johnston)—Male, 50, April 22nd, 1890. Dr. MacDonnell.

SUB-ACUTE LEFT PLEURISY AND EMPYEMA. Chronic aortic endocarditis with hypertrophy and dilatation; chronic adhesive pericarditis; cyanotic induration of kidneys and spleen with thickening of spleen capsule; nutmeg liver; chronic local peritonitis; right inguinal hernia; right hydrocele; necrosing ostitis l. tibia; thrombosis right branch of hepatic artery.

29 (Johnston)—Female, April 22nd, 1890. Dr. Ross.

CHRONIC PHTHISIS, with cavity. Tuberculous laryngitis and tracheitis; chronic adhesive pleurisy and recent tuberculous pleurisy; tuberculous bronchial glands; tuberculous ulceration, small and large intestine; miliary tubercles of kidney and liver; amyloid stomach, bladder, liver, kidney, and pancreas; infarct and tubercle of spleen; bed sores; patency of foramen ovale.

30 (Johnston)—Male 57, April 26th 1890. Dr. Wilkins.

DOUBLE ACUTE PNEUMONIA, of upper lobe; acute left pleurisy; slight chronic endocardits; slight brown atrophy of heart; diverticula of colon; fatty liver; cloudy swelling of kidneys.

31 (Johnston)—Female, 50, May 3, 1890.

CANCER OF UTERUS, infiltrating sigmoid flexure and rectum; secondary cancer of liver; chronic pulmonary tuberculous, miliary tuberculosis of liver; tuberculous peritonitis; cancer of R. ureter R. hydronephrosis; brown atrophy of heart; milk patch.

32 (Johnston)—Male, 22, May 5, 1890. Dr. Ross.

DUODENAL ULCER, perforation, peritonitis and R. pleurisy.

33 (Johnston)—Female, May 5, 1890. Dr. Shepherd.

RENAL CALCULUS, nephrectomy left kidney; pyelonephritis on R. side,

34 (Johnston)—Private Case. Dr. Buller.

SARCOMA OF PITUITARY GLAND, large round-celled; optic neuritis and atrophy.

35 (Johnston)—EMPHYSEMA and œdema of lungs; chronic and acute bronchitis; nutmeg liver, interstitial nephritis (diffuse); dilatation of heart with fatty degeneration; fusion of aortic cusps and sclerosis.

36 (Johnston)—Female 33.

ACUTE LEFT LOBAR PNEUMONIA, both lobes; acute pericarditis; acute R. pleurisy; parenchymatous nephritis and hepatitis; acute swelling of spleen; subinvolution; puerperal state; thrombi beneath placental site, firm acute aortic endocarditis with perforation, and long fibrinous tag attached.

37 (Johnston)—Female, 33.

ACUTE GENERAL PERITONITIS. Chronic and acute parametritis; gangrenous cyst in region of left fallopian tube; cystoma left ovary; R. pyosalpynx.

38 (Johnston)—Male, 10, May, 20, 1890. Private case.

TUBERCULOUS MENINGITIS. Brain only examined.

39 (Johnston)—Male, 49, May 29, 1890. Dr. Ross.

CEREBRAL PLUMBISM. Atrophy of brain cortex; neuro-retinitis; haemorrhage into pons; enlarged spleen; kidneys not cirrhotic.

40 (Johnston)—Male, 42, June 5, 1890.

CHRONIC PHTHISIS WITH CAVITY. Interstitial pneumonia; tubercles in spleen and wall of intestines, Cyst R. epididymis; tuberculous laryngitis; slight mitral endocarditis; tubercles in liver; caseous abscess in wall of bladder.

41 (Johnston)—Male, 7 months. Dr. Corsan.

CHRONIC TUBERCULOSIS, PART OF R. LUNG; chronic pleurisy; acute miliary tuberculous liver, spleen and right lung; caseous epigastric and bronchial glands; tuberculosis of heart muscle and endocardium of mitral ring.

42 (Johnston)—Male, 43, July, 27, 1890.

RIGHT PYELONEPHRITIS. Nephrotomy, purulent cystitis; old stricture of urethra; old mitral endcarditis; old infract of spleen.

43 (Johnston)—Male, 67, July 30, 1890.

ACUTE LOBAR PNEUMONIA. Red hepatization right lower lobe; old infarcts of lung with emphysema of both lungs; hypertrophy and dilatation of heart; fatty liver; infarcts spleen and kidneys.

44 Female (29) August 5. 1890. Dr. Ross.

OBSTRUCTIVE JAUNDICE; acute parenchymatons nephritis; gall stones; liver 2,750 grms.; soft

45 Male (24) Aug 12, 1890. Dr. Shepherd.

RIGHT PYCLONEPHRITIS. Left hydronephrosis; stricture of urethra.

46 Not entered.

47 (Johnston)—Male, 23.

TYPHOID FEVER. Ulceration of solitary follicles in large intestine and of Peyers patches; acute enlargement of spleen and mesenteric glands; cloudy swelling of liver.

48 (Johnston) Male, 61, Sept. 14, 1890.

CHRONIC PHTHISIS, with cavity pulmonary hæmorrhage; recurrent fibro-sarcoma of skin of abdomen.

49 (Johnston) Male, 20, Sept. 24, 1890.

ACUTE PNEUMONIA, right lung; acute double pleurisy; small hæmatomata beneath capsule of spleen.

50 (Johnston) Male, Sept. 24, 1890. Private case.

CEREBRAL HÆMORRHAGE; fine aneurysin of inferior cerebellar artery; slight interstitial nephritis; pressure upon medulla.

51 (Johnston) Female, 39, Oct. 5, 1890. Dr. Bell.

MALIGNANT ADENOMA OF R. KIDNEY and suprarenal; gangrenous and putrid R. perinephritis; old apical tubercles both lungs with acute miliary tubercle apex of R. lung, and acute R. pleurisy; cystoma R. ovary. Anæmia.

52 (Johnston)—Male, 52, Oct. 8, 1890. Dr. Bell.

EPITHELIOMA OF TONGUE. Secondary in lungs; excision of tongue; multiple necrosing pneumonia; arteriosclerosis.

53 (Johnston) Female, 60, Oct. 16, 1890. Dr. Wilkins.

CANCER OF STOMACH, diffuse form with cirrhosis and diminution in size; chronic stenosing mitral endocarditis; brown atrophy heart and liver; calculus of left kidney.

54 (Johnston) Male, 36, Oct. 22, 1890. Dr. Wilkins.

SYPHILITIC ULCERATION OF LARGE INTESTINE, adhesive perityphlitis from ulcer of rectum and descent of rectum on right side; syphilitic ostitis and periostitis of tibia and cranium; œdema of lungs; bronchopneumonia; amyloid kidney and chronic parenchymatous nephritis; ulceration of pharynx; cirrhosis of liver; fæcal concretion in appendix; local adhesive peritonitis.

55 (Johnston) Female, 23, Oct. 28, 1890. Private case.

CHRONIC ULCER OF STOMACH and perforation. Acute purulent perforative peritonitis. Parenchymatous swelling of kidneys and liver, spleen and heart.

56 (Johnston)—Male, Nov. 7, 1890. Verdun Asylum.

DIFFUSE SCLEROSIS OF BRAIN, thickening and opacity of pia; subdural nodule over R. hemisphere; enlargement of supra renals.

57 (Johnston)—Female, 51, Nov. 20, 1890. Dr. Gardner.

SCARCOMA OF UTERUS, abdominal hysterectomy; acute peritonitis with serous effusion; cysts of spleen; arterio sclerosis; elongation left lobe of liver.

58 (Johnston)—Male, 50, Nov. 20, 1890. Dr. MacDonnell.

DIABETES, acetonuria; chronic phthisis; slight interstitial pleuritis; brain normal.

59 (Johnston)—Male, 50, Nov. 22. Private case.

DIABETES, acetonuria; thickening of pia; brain tissue firm but no focal disease; pancreas normal; kidneys large and firm, contain a few cysts.

60 (Johnston)—Male, 40, Dec. 6, 1890. Dr. MacDonnell.

CHRONIC MITRAL AND AORTIC ENDOCARDITIS. Dilatation and hypertrophy of heart; universal adhesive pericarditis; cyanotic induration of lungs, liver and kidneys; old infarcts in spleen and kidneys; anasarca; ascites; R. hydrothorax; chronic left otitis media.

61 (Johnston)—Male, 4, Dec. 6, 1890, Dr. Corsan.

ACUTE BRONCHO-PNEUMONIA and catarrhal rhinitis: polypoid thrombus of R. auricle.

62 (Johnston) Male, Dec. 9. Private case.

CHRONIC PHTHISIS, with cavity of left lung. Left tuberculous pleurisy with effusion; amyloid spleen, liver and kidney.

63 (Johnston)—2½ years, Dec. 10. Private case.

ACUTE BRONCHO-PNEUMONIA, thrombus in longitudinal sinus and right renal vein.

64 (Johnston)—Male, 34, Dec. 20. Dr. Molson.

GONORRHŒAL ULCERATIVE ENDOCARDITIS of tricuspid and aortic valves involving septum membranaceum; slight dilatation and hypertrophy of heart; chalicosis lungs with slaty pigmentation; chronic bronchitis and bronchiectasis; chronic interstitial pneumonia disseminated; chronic purulent urethritis; enlargement of spleen, liver and kidneys.

65 (Johnston)—Male, 30, Dec. 14, 1890. Dr. Molson.

EMPHYSEMA. Dilatation and hypertrophy of heart; cyanotic induration of kidney; multiple sclerosis of brain with superficial hæmorrhages.

66 (Johnston)—Male, 40.

CHRONIC PARENCHYMATOUS NEPHRITIS. Hypertrophy of left ventricle; gliosis; old apoplectic cyst; uræmia.

67 (Finlay)—Male, 54.

STRICTURE OF URETHRA; ENLARGED PROSTATE; cystitis; hydronephrosis; hypertrophy of left ventricle; Liebermeister's furrows.

68 (Finlay)—Male, 21, Dec. 24, 1890.

PROFOUND ANÆMIA; dilatation and hypertrophy of heart; fatty heart; petechiæ mucosa of colon.

69 Male, 19, Dec. 30, 1890. Dr. MacDonnell.

APPENDICITIS, perinephritic abscess; acute purulent peritonitis; acute swelling of spleen, kidneys and liver.

1891

[1 to 19—Records lost].

20 (Johnston)—Male, 28. March 9th, 1891. Dr. MacDonnell.

ADENOID CANCER OF ILEUM near valve; chronic adhesive peritonitis with ulceration and fistula of ileum; cloudy swelling and slight interstitial nephritis.

[21 to 28—Records lost].

29 (Finley)—Male, 55. April 22nd, 1891. Dr. Ross.

CORTICAL HÆMORRHAGE OF BRAIN. Atrophy and hydronephrosis of R. kidney; enlargement (compensatory) of left kidney; fatty and cirrhotic liver; enlarged spleen; old fibroid nodules and adhesions of R. apex; calcareous bronchial glands; œdema of lungs; atheroma of abdominal aorta.

30 (Finley)—Male. 23. May 3rd, 1891.

ACUTE PNEUMONIA, lower lobe of R. lung; acute bronchitis; hypertrophy of left ventricle.

31 Finley)—Male, 59. May 4th, 1891. Dr. Wilkins.

PRIMARY PURULENT PERICARDITIS; slight fibrinous pleurisy.

32 (Finley)—Male, 48. May 11th, 1891. Dr. Wilkins.

ACUTE NEPHRITIS. Hypertrophy of left ventricle with slight fibrosis tip of papillary muscle; right hydrothorax; hydropericardium; œdema of lungs.

[33—Record lost.]

34 (Finley)—Female, 24. May 13th, 1891. Dr. Wilkins.

TUBERCULOUS MENINGITIS. Caseous nodule in cerebellum; bronchopneumonia left lower lobe; cystoma of ovaries; no appearance of miliary tubercles in organs.

35 (Finley)—Female. May 11th, 1891. Maternity.

ACUTE MENINGITIS of pia and dura over left convolutions; no spinal meningitis; no cause discovered; cloudy swelling of liver, kidneys and spleen.

36 (Finley)—Male, 34. May 16th, 1891. Dr. Wilkins.

ACUTE ASCENDING PARALYSIS; no lesions of organs noted at autopsy; brain and cord normal.

37 (Finley)—Male, 42. June 1st, 1891. Dr. Ross.

PNEUMONIA OF RIGHT BASE WITH ACUTE PLEURISY. Cirrhotic kidneys; hypertrophy of left ventricle; cirrhosis of liver; chronic necrosing ostitis of skull cap (syphilitic ?).

38 (Finley)—Female, 18. June 7th, 1891. Dr. Ross.

ACUTE MULTIPLE PNEUMONIA, RIGHT UPPER LOBE. Acute swelling of spleen, liver and kidneys; thrombosis of right iliac vein; catarrhal ulceration of large intestine; old thickening of mitral valves; old infarcts of kidneys.

39 (Finley)—Child, 6 days. May 18th, 1891.

ACUTE CEREBRO SPINAL MENINGITIS. Child of No. 35, 1891.

40 (Finley)—Male, 52. June 20th, 1891. Dr. ROSS.

PERFORATIVE APPENDICITIS. Localized purulent peritonitis; unusual site of appendix; patent tunica vaginalis with communicated peritonitis; cellulitis of abdominal wall; acute right pleurisy; slight atheroma of aortic valves.

40 a (Finley)—Female, 52. June 22, 1891. Dr. ROSS.

PRIMARY CANCER OF BREAST. Secondary in vertebræ, liver, ribs and pleuræ.

41 (Finley)—Female, 4½. June 23, 1891. Dr. Corson.

DIPHTHERIA of pharynx, larynx and trachea; broncho-pneumonia; cloudy swelling of liver.

42 (Finley)—Male, 52. July 7, 1891. Dr. Armstrong.

PYÆMIA. Right empyema; acute left pleurisy; miliary abscesses heart and kidneys; stricture of urethra; chronic dilatation and hypertrophy of bladder: slight atheroma of aortic and mitral valves; gummatous scars of liver and skin; gallstones.

43 (Finley)—Male, 51. July 27, 1891. Dr. Molson.

CANCER OF ŒSOPHAGUS. (Aspiration?) pleuro-pneumonia; acute general peritonitis; secondary cancer of liver, mesentery and omentum; angioma of liver.

44 (Finley)—Female, 22. July 28, 1891. Drs. Shepherd and Birkett.

ABSCESS OF LEFT LOBE OF CEREBELLUM. Chronic inflammation of left tympanum and mastoid; lateral sinus normal. Only head examined.

45 (Finley)—Verdum Asylum case. Dr. Burgess.

SARCOMA OF BRAIN lying to right side of pons and replacing right lobe of cerebellum.

46 (Finley)—Male, 36. Aug. 8, 1891.

FRACTURE OF RIGHT SQUAMO-TEMPORAL BONE. Fracture of right femur and right side of pelvis. Fell down elevator shaft.

47 (Finley)—Male, 58. Sept. 30, 1891. Dr. Armstrong.

TETANUS. Crush of leg; (Ry. accident); amputation twice—first time wound very foul and flaps sloughed; some interstitial nephritis; no tetanus bacilli found in wound; organs showed nothing special.

48 (Finley)—Male, 2½.

ACUTE MENINGITIS. Greenish gelatinous lymph over frontal and parietal lobes; no evidence of tubercles at vessels; interpeduncular space free; tympana normal; non-tubercular.

1892

1 to 19—Reports missing.

20 (Finley)—Female, 40. April 3, 1892. Dr. Armstrong.

CEREBRAL HÆMORRHAGE R. Arteriosclerosis; hypertrophy of left ventricle; cirrhotic kidney; R. kidney converted into a mass of small cysts at its lower end.

21 (Finley)—Infant. April 9, 1892. Maternity.

PYÆMIA. Suppurative omphalo-phlebitis; peritonitis; multiple abscesses; parenchymatous degeneration of liver, spleen and kidneys.

22 (Finley)—Male, 40. April 24, 1892. Private.

FIBROID HEART. Atheroma of aorta; atheroma of coronaries.

23 (Finley)—Male, 24. April 27, 1892. Dr. J. A. Hutchinson.

DEPRESSED FRACTURE OF SKULL. Abscess of left frontal lobe of brain; staphylococcus pyogenes aureus infection.

24 (Finley)—Female, 50. April 28, 1892. Dr. Ross.

ABSCESS OF LIVER. Impacted gallstone; contraction of gall-bladder; dilatation of bile ducts; no jaundice.

25 (Finley)—Male, 60. May 11, 1892. Dr. Wilkins.

PYÆMIA. Abscesses of neck near thyroid; cirrhosis of liver.

26 (Finley)—Male. May 11, 1892.

SACCULATED ANEURYSM OF DESCENDING ARCH OF AORTA. Rupture into œsophagus.

27 (Finley)—Male, 48. May 19, 1892. Dr. Ross.

ACUTE RIGHT LOBAR PNEUMONIA. Calcified adhesions left pleura; milk patches; fatty liver.

28 (Finley)—Female, 34. May 26, 1892. Dr. Finley.

TYPHOID FEVER. PERFORATION AND PERITONITIS. Cloudy swelling of liver and kidneys; spleen small 95 grms; commencing atheroma of aorta.

29 (Finley)—Male, 35. May 27, 1892. Dr. Ross.

MILIARY TUBERCULOSIS OF LUNGS. Caseous tubercles in epididymis and each lobe of prostate; sebaceous cyst of back.

30 (Finley)—Male, 33. May 31, 1892. Dr. Ross.

ANGINA PECTORIS. Atheroma of aorta; atheroma and stenosis of coronary arteries; dilatation and fatty degeneration of heart.

31 (Finley)—Male, 28. June 2, 1892. Drs. Stewart and Ross.

MITRAL STENOSIS. Hypertrophy and dilatation of left auricle; cyanotic induration of lungs.

32 (Finley)—Male, 35. June 8, 1892. Dr. Armstrong.

SPINAL MENINGITIS AND COMPRESSION MYELITIS. Gummatous tumor of cord; gummata in testes, liver, spleen and lungs.

33 (Finley)—Male, 62. June 15, 1892. Dr. Ross.

PRIMARY CANCER IN BILE DUCTS, secondary in liver and glands of portal fissure, also in retro-abdominal and retro-thoracic glands; jaundice.

34 (Finley)—Female, 15. June 16, 1892. Dr. Wilkins.

TUBERCULOSIS OF BOTH LUNGS, WITH CAVITIES. Tuberculous salpingitis; tuberculous peritonitis and tuberculous ulceration of intestines; left pneumothorax.

35 (Finley)—Male, 66. June 19, 1892. Dr. Ross.

ADENOID CANCER OF STOMACH. Secondary cancer of liver; recent peritonitis with effusion; minute fibroid patch in heart; adhesions of bases of lungs.

36 (Finley)—Female, 34. June 21, 1892. Dr. Wilkins.

MILIARY ABSCESSES OF LIVER. Gallstones; dilated bile-ducts; contracted and thickened gall-bladder; old appendicitis.

37 (Finley)—Male, 41. June 21, 1892. Dr. Ross.

TUBERCULOSIS. Tuberculous caries of spine, lumbar region; psoas abscess (double caseous); miliary tuberculosis of lungs, kidneys, liver and spleen; tuberculous meningitis and pericarditis.

38 (Finley)—Male, 64. June 27, 1892. Dr. Bell.

ENLARGED PROSTATE; PYELITIS AND MULTIPLE ABSCESSES OF KIDNEYS. Superficial necrosis of prostate; hypertrophy of bladder.

39 (Finley)—Female, 71. June 28, 1892. Private.

HÆMORRHAGIC INFARCTION AND RUPTURE OF HEART. Sudden death. Calcareous degeneration of coronary arteries, with thrombosis; senile atrophy of kidneys; polypus of cervix uteri.

40 (Finley)—Female, 32. June 30, 1892. Drs. Buller and Stewart.

PHLEGMONOUS ERYSIPELAS OF LEFT LEG AND THIGH. Aortic stenosis; hypertrophy of left ventricle; atheroma of aorta; fibroid testicle (syphilis?).

41 (Finley)—Female, 5. July 3, 1893. Dr. Wilkins.

DIPHTHERIA of larynx and trachea; broncho-pneumonia; inflation of lungs; slight mitral endocarditis.

42 (Finley)—Female, 23. July 10, 1892. Private.

EMBOLI IN VENA CAVA AND PULMONARY ARTERIES. Thrombosis of left iliac vein; œdema of lungs; anæmia; recent pregnancy.

43 (Finley) Male, 19. July 13, 1892. Dr. Ross.

TUBERCULOSIS. Tuberculous caries of dorsal vertebræ; tubercles of lungs, liver, kidneys and spinal membranes; compression myelitis.

44 (Finley) Male, 48. July 19, 1892.

SUPPURATIVE NEPHRITIS. Stricture of urethra; slight hypertrophy of bladder; chronic cystitis; abscess of scrotum; fibroid testicles; emphysema; hypertrophy of heart; atheroma of aorta.

45 (Finley) Female, 33. July 23, 1892. Dr. Wilkins.

ACUTE PERITONITIS and pleurisy; biliary calculi; perforation of gall bladder; ovaries enlarged and fibroid.

46 (Finley)—Male, 11. July 28, 1892. Dr. Wilkins.

TUBERCULOSIS of mesenteric glands, intestines and lungs; acute mitral endocarditis.

47 (Finley) Male, 23. Aug. 1, 1892. Dr. Shepherd.

APPENDICITIS. Pelvic abscess; laparotomy.

48 (Finley) Female, 21. Aug. 2, 1882. Dr. Ross.

PHTHISIS. Large cavities at both apices; tuberculous ulcers of colon; chronic adhesive pelvic peritonitis.

49 (Finley)—Female, 50. Aug. 4, 1892. Dr. Finley.

GLIOMA R. OPTIC THALAMUS. Uterine fibroid; atrophy of organs.

50 (Finley) Male, 31. Sept. 31, 1892. Dr. Stewart.

PULMONARY PHTHISIS OF BOTH LUNGS, WITH CAVITIES. Chronic pleurisy; serous pericarditis; atrophy of right shoulder muscles; suppurative arthritis right shoulder.

51 (Finley) Female, 20. Sept. 4, 1892. Dr. Wilkins.

PYÆMIA. Typhoid fever; suppurative infarctive nephritis; dilatation of R. ureter; subinvolution of uterus; puerperal state; eleventh day after miscarriage (still-born 7 months); swelling of spleen with infarcts; parenchymatous degeneration of liver; acute R. pleurisy.

52 (Finley) Female, 50. Sept. 5, 1892. Dr. Stewart.

BRONCHO-PNEUMONIA. Hypertrophy of heart with adhesive pericarditis; atheroma of aortic valves; atheroma of aorta.

53 (Finley) Female, 28. Sept. 9, 1892. Dr. Ross.

CARBUNCLES; no other gross lesions.

54 (Finley) Female, 48. Sept. 11, 1892. Dr. Shepherd.

MULTIPLE, ANEURYSMS OF SUPERIOR MESENTERIC ARTERY, WITH RUPTURE INTO PERITONEAL CAVITY. Dissecting aneurysm of abdominal aorta; aneurysm of right subclavian; early interstitial nephritis; hypertrophy and fibroid change of left ventricle.

55 (Finley)—Female, 58. Sept. 14, 1892. Dr. Armstrong.

STRANGULATED HERNIA. Hæmorrhagic infiltration of ileum at one point; atheroma of aortic valves.

56 (Lafleur)—Female, 3. Oct. 28, 1892.

SCARLATINA. Pseudomembranous pharyngitis, rhinitis and laryngitis; localized pneumonia of left lung; tuberculous adenitis bronchial glands; bilateral purulent otitis media.

57 (Lafleur)—Male, 3. Nov. 12, 1892.

DIPHTHERIA of tonsils, pharynx and uvula, larynx and trachea; broncho-pneumonia and lung inflation; p.m. invagination of small bowel.

58 (Lafleur)—Male, 43. Nov. 22, 1892.

CHRONIC INTERSTITIAL NEPHRITIS. Chronic right pleurisy; emphysema and œdema of both lungs; chronic gastritis; chronic purulent bronchitis; fatty liver.

59 (Adami) Female. Nov. 23, 1892.

PYÆMIA. Retained suppurati ng placenta; pyæmic infarct lower lobe right lung; right empyæma; varicose veins.

60 (Adami) Female, 32. Nov. 23, 1892.

NECROSIS (GANGRENE?) OF LUNG. Old pleurisy with adhesions; interstitial nephritis; dilatation and hypertrophy of heart with sclerosing endocarditis.

61 (Finley) Male, 26. Dec. 3, 1892. Dr. Bell.

HÆMORRHAGIC PANCREATITIS. Fat necrosis; fatty liver; large firm kidneys; a few ounces of brownish coloured fluid in peritoneum; no peritonitis.

1893

1 to 10—Reports missing.

11 (Adami)—Male, 88. Jan. 23, 1893. Dr. Bell.

CARCINOMA OF PROSTATE extending to the bladder, where it presents characters of an alveolar sarcoma; dilated bladder; secondary cancer in left inguinal glands and (around common iliac arteries); retroperitoneal glands; hydronephrosis; hydrothorax and œdema of lungs; atheroma of aorta, carotids and cerebral arteries.

12 (Adami)—Male, 47. Feb. 10, 1893.

SOFTENING OF LEFT ASCENDING PARIETAL CONVOLUTION. Hypostatic congestion and atelectasis of lungs; fatty liver; thickening of aortic valves; fatty change of kidneys; bedsores.

13 (Adami)—PERNICIOUS ANÆMIA.

14 (Adami) Male, 31. Feb. 22, 1893.

CHRONIC FIBROUS PACHYMENINGITIS near ascending parietal convolution (lower end) with adhesion to pia; heart enlarged and fatty; perihepatitis fibrosa. Paralysis L. leg.

15 (Adami) Male, 35. Feb. 24, 1893. Dr. Stewart.

ARTERIOSCLEROSIS. Hypertrophy and dilatation of heart; embolic infarct of left ventricle; interstitial nephritis; white infarcts of kidneys.

16 (Adami) Female, 72. Feb. 8, 1893. Dr. Stewart.

HYPERTROPHY OF HEART AND CHRONIC ENDOCARDITIS OF MITRAL AND AORTIC VALVES. Hypertrophic ostitis inner table of frontal bone; ivory exostosis of R. petrous bone; calcareous change of arteries at base of brain; hydrothorax; calcification of coronaries; congestion of stomach and intestines; rib indentations on liver; ovaries look cartilaginous; old fracture of R. 3rd, 4th and 5th ribs; œdema of lungs

17 (Adami) Female, 66. March 30, 1893. Dr. Molson.

TUMOR OF CORPUS CALLOSUM L. FRONTAL REGION. Atheroma of abdominal aorta; aneurysmal dilatation of sinuses of valsalva; brown atrophy of heart.

18 (Adami) Male, 71. April 3, 1893.

PYELONEPHRITIS. Phosphatic concretions of bladder; general hypertrophy of prostate; perineal cystotomy; hypertrophy of heart; arterio sclerosis.

19 (Adami) Male, 8 years. April 8, 1893.

TUBERCULOUS MENINGITIS. Acute miliary tuberculosis; tuberculous mesenteric gland; miliary tubercles of spleen and liver and lungs; broncho pneumonia.

20 (Adami) Male, 37. April 11, 1893.

ACUTE TUBERCULAR BRONCHO-PNEUMONIA OF RIGHT LUNG. Symmetrical sclerosis of Gall's column; in lower dorsal region similar degeneration of crossed pyramidal tract; milk spots of heart; dilatation; cavity left apex; constriction anterior of right lobe of liver; tuberculous ulceration of intestines; slight atheroma of aorta; syphilitic gumma of cord.

21 (Adami) Male, 21. April 13, 1893.

AORTIC INCOMPETENCE. Chronic general adhesive pericarditis; dilatation and hypertrophy of heart; persistent foramen ovale; congestion and œdema of lungs; nutmeg liver; hogback kidneys; anasarca.

22 (Adami) Female, 73. April 15, 1893.

MULTIPLE SOFTENING OF CORTEX OF R. HEMISPHERE. Atheroma of cerebral arteries; brown atrophy of liver; accessory spleen; cirrhosis of kidneys; degeneration of supra-renals (gray mottled); dilated and atrophied stomach.

23 (Adami)—Female, 28. April 17, 1893.

MILIARY TUBERCULOSIS OF PIA AND CORTEX. Old phthisis both apices; large cavity of left upper lobe; acute tuberculous broncho-pneumonia; tuberculous right supra-renal; miliary tuberculosis of liver and kidneys.

24 (Adami) Male, 25. May 1, 1893.

ACUTE PNEUMONIA. Old pneumonia of left upper lobe; gangrene; catarrhal jaundice.

25 (Adami)—Female, 55. May 3, 1893. Dr. Blackader.

PYONEPHROSIS. Left hydronephrosis with commencing pyonephrosis; right pyonephrosis with multiple abscesses and purulent perinephritis; cystitis; mixed urate and oxalate calculi; obstruction of ureters.

26 (Adami) Female, 37. May 9, 1893.

WOUND INFECTION OF RIGHT ARM. Septicæmia; congestion of lower lobe of right lung; congestion of kidneys with parenchymatous nephritis and fatty degeneration; fatty liver; hyperostosis frontal bone.

27 (Adami) Male, 44. May 16, 1893.

ACUTE PNEUMONIA of lower lobe of left lung advancing in upper lobe; acute left pleurisy; early interstitial nephritis with acute parenchymatous nephritis.

28 (Adami) Male, 44. May 17, 1893. Dr. Blackader.

EMPHYSEMA. Old tuberculosis both apices; bronchitis; pulmonary œdema and congestion at bases; dilatation and hypertrophy right heart; patent foramen ovale; nutmeg liver; interstitial nephritis; congestion of upper part of intestines; congestion and hæmorrhage of pancreas.

29 (Adami)—Male, 24. May 31, 1893.

ACUTE LOBAR PNEUMONIA right upper and left lower lobes; acute fibrinous pleurisy (double); acute parenchymatous nephritis.

30 (Johnston)—Male, 60. May 31, 1893.

ACUTE LOBAR PNEUMONIA right lung. Disseminated broncho-pneumonia left lung; atheroma and dilatation of aorta; chronic interstitial myocarditis; acute catarrhal gastritis, colitis and cholecystitis; fatty liver; chronic interstitial nephritis; alcoholism.

30A (Adami)—Male, 3. June 5, 1893.

SCARLATINA. Abscess of neck; suppurative lymphangitis; acute parenchymatous nephritis; acute enlargement of spleen; acute pharyngitis; acute and chronic purulent right otitis media and interna; acute right mastoiditis.

31 (Adami)—Male, 59. June 22, 1893.

ANGINA LUDOVICI. Septicæmia; fatty degeneration of heart.

32 (Adami)—Male, 39. June 22, 1893.

HERNIA. Radical cure; external right iliac pricked and ligatured; wound remaining open and suppurating; marasmus.

33 (Adami)—Female, 52. June 24, 1893. Dr. Blackader.

BRONCHITIS AND EMPHYSEMA. Subacute duodenitis and jejunitis; cyst in brain; chronic adhesive pleurisy; perihepatitis; chronic tuberculosis right apex.

33A (Adami)—Male, 37. June 27, 1893.

ACUTE HÆMORRHAGIC PERICARDITIS. Chronic adhesive pericarditis; congestion and œdema of lungs; bedsores.

34 (Adami)—Female, 60. June 30, 1893.

EMPHYSEMA OF BOTH LUNGS. Chronic bronchitis; adhesions at apex and left base; fatty degeneration of heart with hypertrophy; atheroma of coronaries and aorta; granular kidneys; adhesions and calcareous deposit round left ovary; senile atrophy of intestinal walls; hæmorrhages of pancreas.

35 (Johnston)—Male, 33. July 10, 1893.

FATTY AND CIRRHOTIC LIVER. Jaundice; double hydrothorax chronic parenchymatous and interstitial nephritis; hypertrophy of left heart; chronic granular pharyngitis; broncho pneumonia; œdema of lungs.

36 (Johnston)—Female, 3. July 13, 1893.

ACUTE TUBERCULOUS MENINGITIS. Chronic double otitis media (purulent); miliary tuberculosis of lungs, spleen and liver; tuberculous ulceration of colon; chronic tuberculosis of bronchial glands.

37 (Johnston)—Female, 50. July 13, 1893. Dr. Armstrong.

CHRONIC INTERSTITIAL NEPHRITIS. Acute catarrhal ulceration of colon; pigmentation of peritoneum; myoma uteri; adhesive pleurisy and pericarditis; chronic bronchitis; slight hypertrophy and dilatation of heart; anasarca.

38 (Johnston)—Male, 32. July 14, 1893. Dr. Lafleur.

ACUTE LOBAR PNEUMONIA, upper and lower lobes right lung. Imperfect separation of lobes; acute right fibrinous pleurisy; slight interstitial chronic hepatitis; slight cloudy swelling of liver and kidneys; acute enlargement of spleen; slight catarrhal colitis; gall-stone.

39 (Johnston)—Female, 18. July 23, 1893. Dr. Wilkins.

TYPHOID FEVER. Ulceration of ileum stage of healing; perforative appendicitis; suppurative perityphlitis with perforation into cæcum; acute septic pelvic peritonitis; chronic adhesive p ·imetritis; acute parenchymatous nephritis and hepatitis.

40 (Johnston)—Female, 32. July 26th, 1893.

GENERAL TUBERCULOSIS. Hæmorrhages of brain, meninges, stomach and intestines; acute hæmorrhagic tubercular peritonitis; acute tubercular pleurisy; hæmorrhage of myocardium; chronic tuberculous enteritis; acute hæmorrhagic cystitis; left pyelonephritis; cirrhosis of liver and kidneys; miliary tuberculosis of liver; solitary tubercle of brain. Purpura.

41 (Johnston) Female, 42. July 28, 1893. Dr. Gardner.

PYOSALPINX. Laparotomy; hernia of wound; operation followed by constipation and diarrhœa; small abscess of abdominal wall; healed laparotomy incision; local adhesive peritonitis; chronic pelvic peritonitis with recto-vesical fistula receding from region of left fallopian tube; catarrhal cystitis and enteritis; fatty heart; cloudy swelling of liver and kidneys.

42 (Johnston)—Male, 53. July 28, 1893.

CARCINOMA OF RIGHT KIDNEY. Secondary cancer in liver and retroperitoneal glands; perihepatitis; cyst of liver; secondary cancer of left supra-renal; necrosis of right supra-renal; bronzing of skin with slight leucoderma; brown atrophy of heart.

43 (Johnston)—Female, 7. August 5, 1893. Dr. Spier.

TUBERCULOSIS OF BRAIN. Solitary tubercle of cerebellum; acute tubercular meningitis; chronic tuberculosis of bronchial glands.

44 (Johnston) Female, 40. Aug. 7, 1893. Dr. Blackader.

FATTY AND CIRRHOTIC LIVER. Gallstones; acute necrosing mycotic enteritis; acute parenchymatous nephritis; jaundice.

45 (Johnston) Male, 24. August 24, 1893. Dr. Armstrong.

CARIES OF LUMBAR AND SACRAL VERTEBRÆ. Sacro-iliac disease; retroperitoneal pelvic and psoas abscesses; acute miliary tuberculosis; tuberculous meningitis; chronic hyperplasia of spleen; chronic parenchymatous nephritis; nutmeg liver.

47 (Johnston)—Female, 20. August 28, 1893. Dr. Blackader.

OLD EMBOLIC SOFTENING OF CORPUS STRIATUM AND EXTERNAL CAPSULE. Recent embolism of left middle cerebral artery; chronic sclerotic and acute verrucose endocarditis of mitral valve with cyst in valve segment; brown induration of lungs; chronic hyperplasia of spleen with infarcts; cyanotic atrophy of liver; adhesive peritonitis; retroflexed uterus.

48 (Johnston) Male, 41. Sept. 11, 1893.

PRIMARY CARCINOMA OF LEFT BRONCHUS. Secondary in bronchial glands, left lung and liver; subacute broncho pneumonia; cancerous pleurisy and pericarditis; slight parenchymatous nephritis.

49 (Adami)—Female, 49. Sept. 15, 1893.

PHTHISIS. Chronic tuberculosis of right apex with cavity; indurative chronic tuberculosis of left apex; chronic interstitial nephritis diffuse; amyloid kidney; marantic thrombus renal veins; tuberculosis of intestines.

50 (Adami)—Female, 6. Sept. 27, 1893.

SCARLATINA. Enlarged glands of neck with purulent infiltration, extending round larynx and through connective tissue to skin; laryngeal ulcers; broncho-pneumonia with miliary abscesses of lung; parenchymatous nephritis; fatty degeneration of liver; enlarged mesenteric glands.

51 (Adami)—Male, 65. Oct. 5, 1893.

CARCINOMA OF LOWER END OF ŒSOPHAGUS AND CARDIAC END OF STOMACH. Ulceration and perforation; subdiaphragmatic abscess around œsophageal end of stomach; perforation and abscess between pericardium and diaphragm; acute pericarditis.

52 (Adami)—Female, 3. Oct. 9, 1893.

SCARLATINA. Granular pharyngitis; cervical lymphadinitis (non-suppurative); cloudy swelling of heart; clotting in cavæ and veins; slight bronchitis; acute parenchymatous nephritis; dura mater thick.

53 (Adami) Male, 30. Oct. 18, 1893.

ACUTE MANIA. Lungs congested; bronchi full of mucus; no other anatomical changes.

54 (Adami)—Female, 31. Oct. 31, 1893.

ACUTE DIPHTHERITIC ENDOMETRITIS. Subinvolution of uterus; thrombo phlebitis of pelvic veins; pulmonary embolism with multiple pulmonary abscesses; tuberculous ulceration of larynx; tuberculosis of mesenteric glands; parenchymatous swelling of spleen, kidneys and liver.

55 (Adami)—Male, 62. Nov. 2, 1893.

PNEUMONIA. Gray hepatization right middle lobe; interstitial right upper lobe; œdema and congestion right lower lobe; chronic pleurisy with total right adhesions; extreme œdema left lung; hypertrophy and dilatation of heart; hydropericardium; left hydrothorax; chronic fibrinous perisplenitis; submucous rectal lipoma; cirrhosis of liver, early stage; atrophic cirrhosis of kidneys; old healed gastric ulcers; general arterial fibrosis.

56 (Adami)—Male, 35. Nov. 6, 1893.

ABSCESS OF FRONTAL SINUS; MILIARY TUBERCULOSIS. Acute rhinitis; congestion and œdema of lungs with old caseous tubercles and acute tubercles; acute parenchymatous nephritis; acute bronchitis; calcified mesenteric glands; slight tuberculosis of intestines.

57 (Adami)—Male, 51. Nov. 15, 1893.

ACUTE PNEUMONIA. Creeping pneumonia approaching left upper lobe; gray hepatization spreading into left lower lobe; old adhesive left pleurisy, and recent acute double pleurisy; slight acute pericarditis; nephritis, mixed subacute, parenchymatous and interstitial.

58 (Adami)—Male, 47. Nov. 19, 1893. Dr. Stewart.

FIBRO SARCOMA lipomatodes of peritoneum and diaphragm; double sarcomatous pleurisy with effusion; interstitial myocarditis; chronic perihepatitis.

59 (Adami)—Male, 22. Nov. 20, 1893.

Dilatation of stomach; lymphatic enlargement of follicles of jejunum; cloudy swelling of kidneys; fatty liver. Death in convulsions, supposed cerebral syphilis.

60 (Adami)—Female, 30. Nov. 27, 1893.

SUBACUTE TUBERCULOSIS OF BOTH LUNGS. Ulceration of œsophagus (tuberculous); tuberculous ulcer of cæcum; amyloid kidneys and intestine; chronic adhesive pleurisy and peritonitis.

61 (Adami)—Female, 5. Nov. 28, 1893.

DIPHTHERIA of tonsils in stage of healing; acute glomerulo-nephritis; renal calculus; acute catarrhal gastro-enteritis; congestion of lungs; commencing broncho-pneumonia; abnormal lobulation of right lung.

62 (Adami)—Male, 45. Nov. 30, 1893.

CHRONIC INTERSTITIAL AND PARENCHYMATOUS NEPHRITIS. Acute pericarditis with effusion; hypertrophy and dilatation of heart; hydronephrosis and dilatation of ureters from the development of fibrous tissue outside base of bladder; cirrhotic and fatty liver.

63 (Adami)—Male, 33. Dec. 1, 1893.

CHRONIC PARENCHYMATOUS NEPHRITIS with extensive fatty degeneration; commencing interstitial nephritis; concentric hypertrophy of left ventricle; slight fatty liver; slight œdema of lungs; congestion of stomach.

64 (Adami)—Male, 47. Dec. 14, 1893.

ABSCESS OF OCCIPITAL LOBE. Cyst of left frontal lobe; Suppuration into lateral and third ventricles; purulent meningitis; calculi (multiple oxalic acid) in cyst of left kidney; Jacksonian epilepsy; trephining left parietal region; necrosing osteitis of parietal bone.

65 (Adami)—Female, 45. Dec. 16, 1893.

CHRONIC INTERSTITIAL NEPHRITIS. Chronic bronchitis with emphysema; hypertrophy of heart; chronic interstitial myocarditis; moveable left kidney with dilatation of ureter.

66 (Adami)—Male, 19. Dec. 27, 1893.

APPENDICITIS. Acute purulent peritonitis; fatty degeneration of heart; liver pale, mottled, fatty central degeneration; skin subicteroid; solitary ulcer of ileum; perforation and suture; amputation of appendix.

1894

1 (Adami)—Female, 11. Jan. 6, 1894. Dr. Finley.

LEUCHÆMIA; cirrhosis of liver; gastric and intestinal hæmorrhages; enlarged spleen; appendicitis (chronic catarrhal); leuchæmia of liver.

2 (Adami)—Male, 62. Jan. 17, 1894. Dr. Molson.

CEREBRAL SOFTENING. Cyst in right corpus striatum; intermeningeal hæmorrhage; chronic leptomeningitis; general arterio sclerosis; chronic interstitial nephritis; commencing red hepatization of left lung with œdema; acute bronchitis; dilatation and hypertrophy of heart; fibroid spleen.

3 (Martin)—Female, 31. Jan. 18, 1894.

LARYNGEAL DIPHTHERIA. Broncho-pneumonia; caseation of bronchial glands; caseous masses and tubercles in lungs.

4 (Adami)—Male, 19. Jan. 20, 1894. Dr. Bell.

TYPHOID FEVER WITH PERFORATION. Perforative peritonitis; purpuric hæmorrhages of skin; hæmorrhagic nephritis; hæmorrhage of retro-peritoneal glands; hæmorrhage of tongue; osteophytes along longitudinal sinus, inner surface of skull cap.

5 (Adami)—Male, 40. Jan. 26, 1894.

ACUTE MILIARY TUBERCULOSIS OF LEFT LUNG. Old apical tuberculosis calcified; apical calcified nodules of right lung; bronchitis; hæmorrhagic infarction of left lobe; submucous hæmorrhages; infarcts of kidneys; slight fatty degeneration and brown atrophy of heart; hypertrophy of ventricles; atheroma of aorta.

6 (Adami)—Male, 47. Jan. 30, 1894. Dr. Finley.

ACUTE FIBRINOUS PURULENT PERICARDITIS. Chronic tuberculosis of right upper lobe with cavity; putrid bronchitis; emphysema; broncho-pneumonia.

7 (Adami)—Male, 37. Feb. 18, 1894. Drs. Finley and Bell.

AMŒBIC ABSCESS OF LIVER. Cicatrix in colon; acute fibrino serous pericarditis; surgical operation opening of subdiaphragmatic abscess; chronic perisplenitis; old infarct; hogback kidney; acute parenchymatous nephritis; streptococcus infection.

8 (Adami)—Male, 65. Feb. 19, 1894. Dr. Finley.

HÆMORRHAGE OF RIGHT CORPUS STRIATUM. General arterio sclerosis and atheroma; hypertrophy and dilatation of heart; arterio sclerotic granular kidney; emphysema; bronchitis; broncho-pneumonia; cyst of right tunica vaginalis.

9 (Adami)—Male, 23. Feb. 19, 1894. Dr. Molson.

CHRONIC PULMONARY TUBERCULOSIS WITH CAVITIES OF BOTH LUNGS. Interstitial pneumonia; chronic pleurisy; caseation of bronchial glands; slight fatty liver; slight cloudy swelling of kidneys; accessory right supra renal.

10 (Martin)—Female, 19. Feb. 23, 1894. Maternity.

DIPHTHERITIC ENDOMETRITIS AND PHLEGMONOUS VAGINITIS. Hæmorrhagic infarction and miliary abscess of lung and liver; calcified nodules in liver; slight parenchymatous nephritis; slight fatty degeneration of heart; streptococcus infection.

11 (Martin)—Male, 34. Feb. 23, 1894. Dr. Finley.

CHRONIC PARENCHYMATOUS NEPHRITIS. Hydrothorax; hydropericardium; ascites and general anasarca; fatty liver; collapse and slight œdema of lung; thyroid inclusion; infarcts in spleen.

12 (Martin)—Male, 38. March 10, 1894. Dr. Finley.

GRAY HEPATIZATION OF RIGHT LUNG. Chronic parenchymatous nephritis.

13 (Adami)—Male, 61. March 15, 1894. Dr. Finley.

MULTIPLE TUBERCULOUS, ABSCESSES OF BRAIN, in right ascending frontal region and ventricles; basilar meningitis; bronchitis; congestion and œdema of lungs; calcified tubercle at apex; suppurative tonsilitis; suppurative bronchial glands at root of right lung; atheroma; pneumococcus infection.

14 (Adami)—Female, 74. March 22, 1894. Dr. Finley.

HÆMORRHAGE IN RIGHT EXTERNAL CAPSULE. Atheroma of cerebral arteries; hypertrophy of heart; chronic interstitial myocarditis; chronic interstitial nephritis; chronic bronchitis and general emphysema.

15 (Adami)—Female, 26. May 3, 1894.

ACUTE SEPTICÆMIA; acute hæmorrhagic pleurisy and pericarditis; acute parenchymatous nephritis; acute myocarditis; cloudy swelling of liver.

16 (Adami)—Male, 64. April 4, 1894. Dr. Lafleur.

LARGE GRANULAR KIDNEYS; chronic tuberculosis, calcified apex; emphysema; hypertrophy and dilatation of heart; thickening of base of valves; fatty degeneration of heart muscle.

17 (Adami)—Male, 52. May 5, 1894.

TUBERCULOSIS. Caries of ribs.

18 (Adami)—Female, 75.

ATROPHIC CIRRHOSIS OF KIDNEYS. Thickening of heart valves; dilatation and brown atrophy; persistent foramen ovale: œdema of lungs; left hydrothorax; old intracapsular fracture of left femur.

19 (Adami)—Male, 68. May 30, 1894.

CIRRHOSIS OF LIVER. Icterus; enlarged spleen; chronic endarteritis; atheroma of coronaries, aorta and iliacs; moderate cirrhosis of kidneys; old apoplectic cysts in left external capsule and optic thalamus; atrophy of hemispheres; dilated ventricles.

20 (Adami)—Female, 34. June 1, 1894. Dr. Molson.

TUBERCULAR MENINGITIS. Tuberculosis left apex; tuberculosis of uterus; maceration of contained fœtus (7 mos.); tuberculous ulceration of ileum.

21 (Lafleur)—Male, 31. June, 6, 1894.

RECURRENT ENDOCARDITIS, mitral and tricuspid valves. Acute pericarditis; hypertrophy and dilatation of heart; atheroma of coronaries and middle sized arteries; tuberculous nodules at apices of lungs; tuberculosis of larynx; infarcts of spleen and kidneys.

21 a (Adami)—Female, 35. June 9, 1894. Dr. Lafleur.

FLEXURE OF LARGE INTESTINE with constriction and diverticula; old calcerous nodules at apices of lungs; ecchymoses of peritoneum; condylomata of vagina; chronic endometritis: fibro cystic ovary; patent foramen ovale.

22 (Adami)—Female, 39. June 12, 1894. Dr. Kirkpatrick.

STRICTURE OF RECTUM. Perforative peritonitis following operation.

23 (Williams)—Female, 35. June 18, 1894. Dr. Wilkins.

PULMONARY TURERCULOSIS WITH CAVITIES. Tuberculous ulceration of intestines; fatty liver with portal cirrhosis.

24 (Williams)—Female, 34. June 23, 1894. Dr. Alloway.

DOUBLE PYOSALPINX. Acute peritonitis; granular endometritis; small dermoid in right ovary.

25 (Williams)—Male, 23. July 3, 1894. Dr. Blackader.

ACUTE PERICARDITIS with effusion; caseous nodules in apex, calcified; mitral stenosis; chronic sclerotic endocarditis.

26 (Williams)—Male, 26. July 12, 1894. Dr. Wilkins.

HYPERTROPHY AND DILATATION OF HEART. Syphilitic endarteritis; bedsores; chronic perisplenitis with calcareous nodules.

27 (Williams)—Female, 56. July 26, 1894. Dr. Shepherd.

BILIARY CIRRHOSIS; nutmeg liver; cirrhosis of kidneys; aneurysm of cirrhosis splenic artery and calcified thrombus.

28 (Williams)—Female, 40. Aug. 7th, 1894.

TUBERCULOUS BASILAR MENINGITIS. Tuberculosis of lungs; general miliary tuberculosis.

29 (Williams)—Female, 38. Aug. 7, 1894. Dr. Wilkins.

LYMPHO-SARCOMA OF BRONCHIAL GLANDS. Compression of right bronchus and partial compression of trachea; acute right pleurisy.

30 (Adami)—Male, 32. Oct. 1894. Dr. Kirkpatrick.

SUPPURATIVE PACHY AND LEPTOMENINGITIS. Cellulitis of scalp and frontal region; enlarged spleen; fatty degeneration of liver and kidneys; cloudy swelling of muscles; suppurative ostitis and periostitis of frontal bone; no abscess of brain.

31 (Williams)—Female, 70. Oct. 21, 1894. Dr. Molson.

INTESTINAL OBSTRUCTION FROM CANCEROUS STENOSIS OF UPPER PART OF RECTUM. Submucous hæmorrhages of descending colon; chronic interstitial nephritis; arterio-sclerosis; brown atrophy of liver and heart; slight acute fibrinous peritonitis; retroperitoneal glands normal; preliminary operation, to lumbar cholotomy.

32 (Johnston)—Female, 38. Oct. 21, 1894. Dr. Finley.

ANEURYSM OF TRANSVERSE ARCH OF AORTA. Erosion of bodies of 4th and 5th dorsal vertebræ; compression of left bronchus and lung; ulcerative and bronchiectatic cavities of left lung, non-tuberculous with chronic adhesive pleurisy; chronic peritonitis and perihepatitis; chronic interstitial nephritis; chronic sclerotic mitral and aortic endocarditis; subperitoneal myoma of uterus.

33 (Williams)—Female, 17. Nov, 11, 1894. Dr. Armstrong.

APPENDICITIS. Laparotomy; acute septic peritonitis.

34 (Williams)—Male, 36. Nov. 14, 1894. Dr, Finley.

TUBERCULOSIS. Miliary tuberculosis and cheesy tubercles in both lungs; miliary tuberculosis of kidneys; cloudy swelling of kidneys; bronchopneumonia; old amputation of right leg, conical stump.

36 (Williams)—Female, 18. Nov. 18, 1894.

ACUTE LEFT PLEURISY; œdema of lungs; acute hyperplasia of spleen.

37 (Williams)—Male, 44. Nov. 23, 1894. Dr. Finley.

HYPERTROPHIC BILIARY CIRRHOSIS. Great enlargement of spleen; œdema of lungs; catarrhal gastritis; ascites; general anasarca; no obstruction of ducts.

38 (Williams)—Female, Nov. 24, 1894.

TYPHOID FEVER. Typhoid ulceration of ileum and colon; enlargement of spleen; hæmorrhagic infarction of lungs; small lymphomata in liver.

39 (Williams)—Female, 20. Nov. 26, 1894.

TYPHOID FEVER. Typhoid ulceration of intestines; acute enlargement of spleen; angioma of liver and calcified nodules.

40 (Williams)—Male, 32. Nov. 28, 1894. Dr. Molson.

CHRONIC ULCERATIVE PHTHISIS BOTH LUNGS. Chronic pleurisy tuberculous ulceration of ileum and colon.

41 (Williams)—Female, 19. Dec. 1, 1894. Drs. Finley and Armstrong.

WOUND OF CORONARY VEIN. Hæmorrhage (22 ℥) into pericardium; puncture of pericardium: acute pericarditis with effusion.

42 (Williams)—Male, 70. Dec. 10, 1894.

BRONCHO-PNEUMONIA. Putrid bronchitis and bronchiectasis; chronic interstitial nephritis; catarrhal enteritis; perforation of cavity into pleura with circumscribed adhesive pleurisy; no hydrothorax; anthracosis.

13 (Williams) Female, 74. Dec. 16, 1894. Drs. Finley and Armstrong.

Erysipelas. Abrasion of chin; recent parenchymatous nephritis; fatty kidneys and liver; atheroma of heart valves and arteries with fatty degeneration.

14 ( ) Female, 34. Dec. 18, 1894.

Report missing.

15 (Williams) Female, 66. Dec. 19, 1894. Dr. Molson.

Fat infiltration of heart; moderate chronic interstitial nephritis; nutmeg liver, amyloid; large soft spleen; tuberculous ulceration? in colon; died comatose, brain not examined.

16 (Williams) Female. Dec. 21, 1894. Dr. Armstrong.

Report missing.

1895

1 (Williams) Male, 22. Jan. 14, 1895. Dr. Molson.

Chronic Mitral Endocarditis with Stenosis. Chronic interstitial nephritis; nutmeg liver; œdema of lungs.

2 (McKenzie)—Male, 50. Jan. 8, 1895. Dr. Finley.

Carcinoma of Liver. Congestion and œdema of lungs; enlarged spleen; submucous hæmorrhages of bladder; chronic gastritis, with slaty pigmentation.

3 (Johnston)—Female, 26. Jan. 20, 1895. Dr. Molson.

Hypertrophy and Dilatation of heart, with fatty degeneration; nutmeg liver; beefy kidneys; fæcal concretion in appendix.

4 (Williams)—Female, 33. Jan. 29, 1895. Dr. Alloway.

Acute Septic Peritonitis. Ruptured tubal pregnancy; laparotomy.

4 a (Johnston) Male, 48. Feb. 18, 1895. Dr. Molson.

Chronic Myelitis in Dorsal Region. Sloughing balanitis; bed sores.

5 (Johnston) Female, 38. Feb. 19, 1895. Dr. Molson.

Puerperal Septicæmia? Papular dermatitis; old cicatrix of epiglottis; concentric hypertrophy of heart; acute hyperplasia of spleen; acute parenchymatous nephritis; chronic endometritis; uterine polyp; recent pregnancy; puerperal state; chronic gastritis; acute cloudy swelling of liver; acute bronchitis; pneumococcus infection; history of influenza.

(Johnston) Male, 39. March 1, 1895. Dr. Finley.

Acute Tuberculous Meningitis; enlarged heart; acute hæmorrhagic cystitis. No primary source of tubercle discovered.

7 (Johnston)—Female, 33. March 3, 1895. Dr. Armstrong.

Acute Septic Peritonitis. Pyosalpinx; laparatomy.

8 (Johnston)—Child, 2. March 2, 1895.

SEPTICÆMIA; purpura. Cause not discovered.

9 (Johnston) Female, 27. March 8, 1895. Dr. Finley.

Syphilitic endarteritis of right sylvian artery, with thrombosis; softening of right internal capsule; slight cirrhotic kidney; brown atrophy of liver.

10 (Johnston) Male, 12. March 9, 1895. Drs. Molson and Armstrong.

ACUTE SEPTIC MENINGITIS from otitis media. Purulent mastoiditis; trephining.

11 (Johnston) Male, 74. March 18, 1895. Dr. Finley.

GLOBULAR HEART THROMBUS. Hypertrophy and dilatation of heart, with chronic interstitial myocarditis and parietal thrombi in left auricle; embolism of right popliteal artery; cirrhosis of liver; slight hypertrophy of prostate; embolism of mesenteric artery: gangrene of ileum.

12 (Johnston)—Male, 72. March 22, 1895. Dr. Armstrong.

ENLARGED PROSTATE, CASTRATION, PYÆMIA. Purulent infection of wound; operation—fistula of urethra in perineo; recto vesical fistula; (healed, leaving blind fistulæ of bladder and rectum); chronic purulent right vesiculitis; slight left hydronephrosis; hæmorrhoids; cloudy swelling of kidneys; induration of prostate with hypertrophy of middle lobe; chronic perihepatitis; enlarged spleen; obsolescent apical cavities; congestion and œdema of lower lobes of lungs.

13 (Johnston)—Female, 21. March 23, 1895. Dr. Finley.

VALVULAR HEART DISEASE. Hypertrophy and dilatation of heart; chronic stenosing mitral endocarditis; recurrent aortic endocarditis; parietal thrombosis in left ventricle; chronic enlargement of spleen; concretion in vermiform appendix.

14 (Johnston)—Female, 37. March 27, 1895. Dr. Finley.

SYPHILITIC ENDARTERITIS OF ANTERIOR AND MIDDLE CEREBRAL ARTERIES WITH THROMBOSIS. Diffuse sclerosis of brain; emphysema; brown atrophy of heart; elongated left lobe of liver.

15 (Johnston) Female, 25. March 28, 1895. Dr. Finley.

ACUTE BRONCHO-PNEUMONIA. Acute fibrinous pleurisy; acute pericarditis with effusion; concentric hypertrophy of heart; acute mitral endocarditis; acute parenchymatous nephritis; cloudy swelling of liver.

16 (Johnston)—Male, 25. March 28, 1895. Dr. Finley.

ACUTE PLEURO PNEUMONIA, right upper and left lower lobes. Thickening and opacity of pia; sclerosis of brain; fibrous interstitial pneumonia and chronic pleuritis left upper lobe; concentric hypertrophy of left heart; chronic interstitial myocarditis; enlarged spleen; hogback kidney.

17 (Johnston)—Female, 50. March 29, 1895. Dr. Molson.

ACUTE GREY HEPATIZATION LEFT LOWER LOBE AND RIGHT MIDDLE LOBE. Chronic bronchitis and emphysema; recurrent mitral endocarditis, with stenosis; polypoid thrombus from mitral valve; atheroma of aorta; lemon colour of fat; anæmia; slight interstitial nephritis; subperitoneal myomata of uterus.

18 (Johnston) Male, 60. March 29, 1895.

ACUTE PNEUMONIA. Acute pleurisy right lung; congestion and œdema left lung; acute sero-fibrinous pericarditis; hypertrophy of heart; chronic mitral and aortic endocarditis; p.m. gastro-malacia; hypertrophy of adrenal; slight double hydrocele; Liebermeister grooves of liver.

19 (Johnston)—Female, 31. April 4, 1895. Dr. Armstrong.

GENERAL SEPTICÆMIA. Extraction of teeth; gangrenous stomatitis; sub-cutaneous ecchymosis; streptococcus infection; anterior extremities of ribs twisted; acute hæmorrhagic gastritis; acute colitis; acute nephritis papillaris and acute double hæmorrhagic pyelitis; cloudy swelling of liver and kidneys; enlargement of uterus; lacing lobe of liver; acute hyperplasia of spleen; accessory spleen.

20 (Johnston)—Male, 61. April 7, 1895. Dr. Finley.

CHRONIC INTERSTITIAL NEPHRITIS. Anæmia; dropsy; double hydrothorax; hydropericardium; dilatation and hypertrophy of heart; slight interstitial myocarditis; brown atrophy of fibres; no fatty change in heart; dilatation of aorta; intense œdema of lungs; emphysema; old caseous mass at right apex; broncho-pneumonia; hypertrophy of right and middle lobes of prostate, with adenoma; lemon-yellow skin; hyperplasia of bone marrow.

21 (Johnston)—Female, 50. April 23, 1895. Dr. Blackader.

CHRONIC ULCERATIVE PHTHISIS right upper lobe. Ochre coloured fat; bifid ensiform; acute tuberculosis of lower and middle lobes; inflation of right lung; chlorosis of aorta; hyperplasia; brown atrophy of heart; nutmeg liver.

22 (Johnston) Female, 24. April 26, 1895.

ACUTE SEPTIC PERITONITIS. Laparotomy; old caseous nodule in mesentery; menstrual state; cyst of right ovary.

23 (——)—Male, 27. April 26, 1895. Dr. Blackader.

Notes not entered.

24 (Williams)—Male, 41. April 30, 1895. Dr. Wilkins.

ACUTE CROUPOUS PLEURO-PNEUMONIA OF LEFT LUNG. Double left ureter; aneurysm of left renal artery; acute degenerative parenchymatous nephritis; pneumococcus infection.

25 (Williams)—Male, 60. May 18, 1895. Dr. Blackader.

RECURRENT ENDOCARDITIS WITH MITRAL STENOSIS. Bedsore; œdema of feet; ascites; chronic fibrous perihepatitis; cirrhosis of liver; thrombosis of portal vein; left hydrothorax; brown induration and œdema of lungs; emphysema; hypertrophy of heart.

26 (Johnston) Male, 53. May 19, 1895. Dr. Wilkins.

DISSECTING BRONCHO-PNEUMONIA WITH NECROSING PLEURISY. Chronic putrid bronchitis and bronchiectasis; localized left empyema gangrenosa; chronic interstitial nephritis; enlargement of prostate.

27 (Williams)—Male, 49. May 20, 1895. Dr. Wilkins.

CHRONIC ULCERATIVE PHTHISIS OF BOTH LUNGS. Universal pleuritic adhesions; chronic interstitial and acute parenchymatous nephritis; chronic interstitial hepatitis; fibrous perihepatitis; ascites.

28 (Johnston) Male, 21. May 21, 1895.

ACUTE TUBERCULOUS MENINGITIS. Tuberculosis of thoracic duct, caseous masses in bronchial glands; miliary tuberculosis of kidney; acute broncho pneumonia; recurrent endocarditis.

29 (Johnston) Male, 2½. May 21, 1895. Dr. Wilkins.

TUBERCULOUS MENINGITIS. Solitary tubercle of corpus collosum; miliary tuberculosis of lungs; caseous tubercles of bronchial and mesenteric glands.

30 (Johnston)—Female, 39. May 27, 1895. Dr. Blackader.

ACUTE TUBERCULOUS MENINGITIS. Acute miliary tuberculosis of lungs; acute parenchymatious nephritis.

31 (Williams)—Female, 55. May 31, 1895. Dr. Wilkins.

VILLOUS (PAPILLARY) CANCER OF UTERUS, secondary in bladder; recto-vesico vaginal fistula; recurrent mitral endocarditis; hæmorrhagic infarction and brown induration of lungs; chronic interstitial nephritis; secondary cancer of inguinal glands.

32 (Johnston) Female, 35. May 25, 1895.

CARBOLIC ACID POISONING. Tanning of stomach and adjacent organs; sub-pleural ecchymosis; hæmatoma of right ovary; slight granular kidneys.

33 (Johnston)—Male, 40. May 24, 1895.

LAUDANUM POISONING. Permanganate solution in lungs; œdema of glottis.

34 (Johnston)—Female, 2½. June 6, 1895. Dr. Hutchison.

ACUTE TUBERCULOUS MENINGITIS. Tuberculous arthritis left hip joint with cold abscess; left hydronephrosis.

35 (Johnston)—Male, 19. June 10, 1895. Dr. Blackader.

CHRONIC PARENCHYMATOUS NEPHRITIS. General anasarca; old excision of elbow joint; caries of both elbow joints; atelectasis and compression of left lung; left hydrothorax; left acute pleuritis; diplococcus infection; obsolescent tubercle R apex; milk patch of heart; ascites and acute sero-fibrinous peritonitis; chronic catarrhal gastritis.

36 (McKenzie)—Female, 24. June 21, 1895. Dr. Shepherd.

FRACTURE OF SKULL, ribs and chavicle; rupture of spleen; hæmorrhage into peritoneum; gestation 5th month; calcified nodules of spleen and liver capsules.

37 (Johnston)—Female, 60. June 24, 1895. Dr. Hutchison.

SLIGHT BRONCHO-PNEUMONIA. Old fracture through head of tibia; old cyst in left frontal lobe of brain; senile granular kidneys; œdema of lungs; calcified plate in heart wall; chronic local adhesive peritonitis; old scar in upper part of rectum; obsolete apical cavities.

38 (Johnston)—Male, 30. July 4, 1895. Dr. Shepherd.

RUPTURE OF LIVER; LACERATION OF LEFT LUNG. Compound fracture of left leg; fracture of lower end of R. tibia; laceration of scalp; ecchymosis of serosa of ascending colon; fracture of ribs; pleuritic adhesions; hæmorrhage into lung tissue; laceration of R. kidney; fracture of transverse process of lumbar vertebra.

39 (Johnston)—Male, 65. July 7, 1895. Dr. Blackader.

ACUTE BRONCHO-PNEUMONIA. Acute pleurisy; hypertrophy of heart; atheroma of coronaries; recurrent aortic endocarditis; emphysema; cheesy nodule in spleen; chronic interstitial nephritis with retention cysts; enlarged prostate; cirrhotic and fatty liver; œdema of pia.

40 (Johnston)—Male, 53. July 8, 1895.

CRUSH OF CHEST. Multiple contusions; laceration of face; fracture of alveolar process; fracture of ribs; left hæmothorax; laceration of pericardium and heart; laceration of spleen.

41 (Johnston)—Male, 27. July 13th, 1895. Dr. Hutchison.

PERFORATED APPENDIX. Acute septic peritonitis (slight); septic perityphlitis; abscess of mesenteric glands; slaty pigmentation of Peyer's patches; acute septic pleurisy (slight); œdema and congestion of lungs; food in bronchi; cloudy swelling of spleen and kidneys.

42 (Johnston)—Male, 25. July 13th, 1895. Dr. Armstrong.

INTESTINAL OBSTRUCTION. Chronic adhesive fibrinous peritonitis; resection of intestines.

43 (Johnston)—Female, 65. July 15th, 1895. Drs. Wilkins and Kirkpatrick.

CHRONIC INTERSTITIAL AND ACUTE PARENCHYMATOUS NEPHRITIS. Chronic adhesive pericarditis; chronic mitral endocarditis with stenosis; fatty degeneration of heart.

44 (Williams)—Female, 44. July 17th, 1895. Dr. Blackader.

TUBERCULOSIS WITH CAVITIES IN BOTH LUNGS. Ochre coloured fat; chronic mitral endocarditis with stenosis; tuberculous mesenteric glands; chronic interstitial nephritis; nutmeg liver with tubercles; healed tuberculous ulcer of intestines; subperitoneal myomata uteri; amyloid kidney (slight).

45 (Williams)—Male, 25. July 17th, 1895. Dr. Blackader.

ACUTE LOBAR PNEUMONIA. Left lower, right lower and middle lobes; double acute fibrinous pleurisy; obsolete tubercles at apex; enlarged spleen; fatty liver.

46 (Williams)—Male, 45. July 18th, 1895. Dr. Wilkins.

PHLEGMONOUS ERYSIPELAS of right leg; bubo in right groin; cloudy swelling of heart and kidneys; old apical tuberculosis; nutmeg liver; atheroma of aortic valves and coronaries; streptococcus infection.

47 (Johnston)—Male, 20. July 19th, 1895. Dr. Kirkpatrick.

APPENDICITIS; ACUTE SEPTIC PERITONITIS. Mixed infection B. coli and streptococci; sinus from behind cæcum to left side of pelvis; brown atrophy of liver; cloudy swelling of kidney.

48 (Williams)—Female, 50. July 21st, 1895. Dr. Alloway.

TUBERCULOUS SALPYNGITIS; ACUTE MILIARY TUBERCULOSIS of lungs and spleen. Removal of appendages; hypertrophy of heart; slight fatty degeneration; chronic interstitial and parenchymatous nephritis; fatty liver and kidney.

49 (Johnston)—Male, 22. July 22nd, 1895. House of Refuge.

GENERAL TUBERCULOSIS. Emaciation; anasarca; large caseous tubercles; tuberculous periostitis of ribs; tuberculous caries of dorsal vertebræ; prevertebral abscess; acute pneumonia left upper lobe; œdema and slight pneumonia of right lung; fatty degeneration of heart; tubercles in spleen; acute parenchymatous nephritis; tuberculous infarct of kidney; œdema of rectum; caseous mass in pancreas; conglomerate tubercles of liver: tuberculous inguinal glands; old bullet wound right temple, perforating skull cap, bullet in situ; exostosis of right temporal bone; softening of right motor area of cortex and subjacent white substance.

50 (Johnston)—Female, 22. July 23rd, 1895. Dr. Alloway.

ADENOID CANCER OF SIGMOID FLEXURE. Secondary in omentum; intestinal obstruction and intestinal hæmorrhage; subacute adhesive peritonitis; distention of ileum; hæmorrhagic colitis; dysentery; P. M. gastro malacia; cloudy swelling of kidney.

51 (McKenzie)—Male, 68. July 25th, 1895. Dr. Blackader.

MELANOTIC SARCOMA left foot; secondary in inguinal glands; multiple cutaneous sarcoma; secondary growths in liver, heart, stomach and pancreas; jaundice; anasarca.

52 (John-ton)—Male, 23. August 14th, 1895. Dr. Wilkins.

ABSCESS AND PHLEGMON OF PROSTATE. Acute septic broncho-pneumonia; phlegmon of wall of bladder; chronic enlargement of spleen; solitary tubercle of mesentery; staphylococcus infection.

53 (Williams)—Female, 27. August 18th, 1895. Dr. Blackader.

TYPHOID. Obsolete tubercle of lungs; subinvolution of uterus; ulceration of intestines; enlarged spleen; cloudy swelling of kidneys.

54 (Johnston)—Female, 3. August 23rd, 1895. Dr. Armstrong.

TUBERCULOUS MENINGITIS. Acute miliary tuberculosis; granulations of ependyma; chronic tuberculosis of liver, lungs and kidneys; cyst of broad ligament.

55 (Johnston)—Male, 23. August 30th, 1895. Dr. Shepherd.

CRUSH OF CHEST. Laceration of cheek; fracture of alveolar process of left superior maxilla; interstitial emphysema; separation of both sterno-clavicular joints and cartilages of both first ribs; left hæmothorax; laceration of lungs with congestion and œdema; ecchymoses of larnyx; chronic interstitial nephritis; enlarged intestinal follicles; hæmorrhage into right tympanic cavity; laceration of tympanum.

56 (Johnston)—Male, 28. Sept. 7th, 1895. Dr. Wilkins.

HÆMORRHAGE OF BRAIN FROM LEFT SYLVIAN ARTERY. Internal hæmorrhagic pachymeningitis; hæmorrhage external ventricle; old spot of softening in right internal capsule; hyperæmia of lungs; large firm spleen; atheroma of aorta.

57 (Johnston)—Male, 70. Sept. 11, 1895. Dr. Hutchison.

CRUSH OF CHEST. Trolley car accident. Right hæmothorax and hæmopericardium; laceration of right lung; fracture of ribs; hæmorrhage of lesser omentum; gallstones; abnormal liver.

59 (Johnston)—Male, 88. Sept 15, 1895.

FRACTURE OF SKULL WITH MENINGEAL HÆMORRHAGE. Run over by butcher's cart. Contusion right side of head; hæmatoma beneath scalp; osteo sarcoma of orbital plate; contusion of brain; atheroma of cerebral arteries with aneurysms; fatty degeneration of vessels of brain; atheroma of aortic valves; hypertrophy and brown atrophy of heart; granular kidneys; brown atrophy of liver.

60 (Johnston)—Male, 9. Sept. 16, 1895.

FRACTURE OF LEFT FEMUR. Multiple contusions; fat embolism of lungs.

61 (Johnston)—Male, 36. Sept. 16, 1895.

PLUMBISM. Chronic alcoholism; hypertrophy of heart; chronic interstitial nephritis; fatty and cirrhotic liver; general arterio-sclerosis; congestion and œdema of lungs; œdema of larynx.

62 (Johnston)—Male, 24. Sept. 16, 1895. Drs. Wilkins and Lafleur.

TYPHOID FEVER. Typhoid ulcers of appendix; congestion of brain; ochre coloured fat; chronic mitral endocarditis; congestion of lungs with apoplexy: acute parenchymatous nephritis and hepatitis; swelling of bronchial glands.

63 (Johnston)—Male, 71. Sept. 21, 1895. Dr. Shepherd.

REVOLVER WOUND OF RIGHT TEMPLE. Trephining; contusion of dura and adjacent part of brain; powder grains in brain; slight nutmeg liver; acute sclerotic kidney; anthracosis; acute broncho-pneumonia; milk patch of heart; atheroma of valves. Suicide.

64 (Johnston)—Female, 6. Sept. 23, 1895. Dr. Blackader.

TUBERCULOUS ENTEROCOLITIS AND PERFORATIVE PERITONITIS. Tuberculous mesenteric glands; tuberculous salpingitis; ulcerative tuberculosis both lungs; tuberculous bronchial glands; fatty liver.

65 (Johnston)—Male, 23. Sept. 24, 1895. Dr. Armstrong.

LARYNGEAL DIPHTHERIA. Phlegmon of neck: tracheotomy; diphtheritic bronchitis; acute parenchymatous nephritis and hepatitis; chronic mitral endocarditis; congestion and œdema of lungs (asphyxia); sub-endocardial ecchymoses.

66 (Johnston)—Male, 53. Sept. 26, 1895. Dr. Wilkins.

PERNICIOUS ANÆMIA. Dilatation and fatty degeneration of heart; chronic pericarditis; emanciation; sub-icterus; atheroma of coronaries; emphysema: œdema of lungs; enlargement of spleen; chronic proliferative gastritis with polypoid outgrowth; slight interstitial nephritis; brown atrophy of liver; iron reaction; fatty degeneration of the central zones; slight lymphoid hyperplasia of red marrow.

67 (Johnston)—New born child. September 26th, 1895.

MUCUS IN TRACHEA. Ecchymosis of pleura and thymus.

68a (Johnston)—Male. September 28th, 1895. Dr. Armstrong.

FRACTURE OF RIGHT CLAVICLE AND STERNUM. Epithelioma of penis and paraphimosis; ulcerative balanitis; double hæmothorax; milk patch; slight atheroma of aorta; chronic interstitial and parenchymatous nephritis.

68 (Johnston)—Male, 28. September 30th, 1895. Dr. Armstrong.

STRANGULATION OF INTESTINES. Chronic adhesive peritonitis; resection of intestines; hyperplasia of spleen; follicular ulceration of rectum; cryptorchidismus; congestion and apoplexy of lungs.

69 (Johnston)—Male, 27. October 4th, 1895. Dr. Armstrong.

TYPHOID FEVER. Perforation; suture of intestine; acute septic peritonitis; typhoid ulceration; follicular ulcers of colon with induration; acute hyperplasia of spleen; slaty pigmentation of rectum; fatty degeneration of intima of coronaries; œdema of lungs; subarachnoid œdema; fibrinous nodules in pia; chronic leptomeningitis; pure culture of typhoid bacilli from spleen.

70 (Johnston)—Male, 68. October 10th, 1895. Dr. Lafleur.

ACUTE BRONCHO PNEUMONIA. Chronic bronchitis and emphysema; interstitial nephritis; brown induration of lungs; slight cirrhosis of liver, with dilatation of central veins.

71 (Johnston)—Male, 33. October 15th, 1895. Dr. Finley.

SYPHILITIC GUMMA OF HEART WALL AND VALVES. Chronic sclerotic endocarditis; gumma of testis; hypertrophy and dilatation of heart; ascites; arteriosclerosis; brown induration of lungs; diffuse interstitial nephritis; acute and chronic gastritis; red atrophy of liver, with chronic diffuse interstitial hepatitis and gumma; sclerosis of pancreas.

92 (Johnston)—Male, 21.

TYPHOID FEVER. Supposed injury of abdomen. Typhoid ulceration of intestine, early stage; ascarides; enlargement of mesenteric glands and spleen; subpleural ecchymosis; cloudy swelling of kidneys and liver; slight atheroma of aorta; acute bronchitis; caseous and calcareous bronchial glands; typhoid culture from spleen and lungs.

73 (Johnston)—Male, 39. Dr. Armstrong.

APPENDICITIS—Operation. Septic thrombophlebitis of portal and mesenteric veins; multiple abscesses of liver; interstitial nephritis; round ulcer of stomach; healed typhoid ulcers of intestines; old tuberculosis of lungs; slaty pigmentation, congestion and œdema of lungs; mixed infection by intestinal bacteria.

74 (Johnston)—Male, 55. October 26th, 1895. Dr. Hutchison.

PRIMARY EPITHELIOMA OF BLADDER. Calculus of bladder; suprapubic cystotomy; secondary growth in vena cava, renal veins, lumbar vertebræ, heart, lungs, liver, pancreas and doudenum; cancerous thrombosis of vena cava inferior; chronic mitral and tricuspid endocarditis; round ulcer of duodenum; diphtheritic pyelonephrosis; scar of prepuce.

75 (Johnston)—Female, 49. October 29th, 1895. Dr. Finley.

PUERPERAL FEVER. Laceration of vagina; pelvic abscess; septic endometritis and phlebitis; subinvolution; omental hernia; chronic adhesive peritonitis; hydropericardium; hypertrophy and dilatation of heart; slight fibroid endocarditis; acute parenchymatous nephritis and hepatitis; thrombosis and abscess of left innominate and jugular veins; streptococcus infection.

76 (Johnston)—Male, 72. October 29th, 1895. Dr. Kirkpatrick.

FRACTURE OF RIGHT FEMUR. Multiple bruises; hypertrophy of heart slight fibroid palillary myocarditis; marginal emphysema; granular (contracted) kidneys; slight double hydrocele (senile); alcoholism gallstones; cause of death: shock following fracture.

77 (Johnston)—Male, 5. October 30th. Dr. Molson.

CARIES OF DORSAL VERTEBRÆ. Tuberculous peritonitis; prevertebral abscess and sinus into cavity of right lung; abscess of spinal dura; transverse compression myelitis with ascending and descending degeneration; thrombosis and caseous infection of cerebral sinuses and veins; dorsal kyphosis; bedsores; bronchitis; disseminated tubercles of pia; caseous mesenteric glands; right caseous pneumonia; caseous bronchial glands.

78 a (Johnston)—Male, 12. November 7th, 1895. Dr. Gardner.

SUPPURATIVE RIGHT OTITIS MEDIA. Right mastoiditis; septic thrombosis of right lateral sinus and jugular; right multiple necrosing pneumonia with putrid right empyæma; chalky mass in lower lobe of left lung; enlargement of spleen.

78 (Johnston)—Female, 28. November 4th, 1895. Dr. Lockhart.

PAPILLOMATOUS CYSTOMA OF OVARY; ACUTE PERITONITIS. Old retroperitoneal hematocele, calcified; laparotomy; slight cloudy swelling of kidneys; old partial obliterative appendicitis.

79 (Johnston)—Male, 54. Nov. 12, 1895. Dr. Finley.

ACUTE LOBAR PNEUMONIA. Aneurysm of ascending arch of aorta; apical scars and tubercles; atheroma of heart valves; cyanotic induration of kidney; nutmeg liver; chronic enlargement of spleen.

80 (Johnston)—Male, 20. Nov. 13, 1895. Dr. Molson.

PHTHISIS. Chronic ulcerative tuberculosis of lung and larynx; tuberculosis of appendix; mitral endocarditis and stenosis; atheroma of coronaries; acute pneumonia with multiple cavities; chronic bronchitis emphysema; acute tuberculous pleurisy; tuberculous perichondritis of larynx; incipient tuberculosis of colon; ascarides; brown atrophy of liver; thickening of pia.

81 (Johnston)—Male, 35. Nov. 14, 1895. Dr. Kirkpatrick.

CANCER OF PYLORUS (scirrhous); laparotomy; slight mitral sclerosis; slight fibrous myocarditis; hyperæma and œdema of lungs; adenoma of left adrenal; sclerosis of pia.

82 (Johnston)—Male, 50. Nov. 18, 1895. Dr. Kirkpatrick.

CRUSH OF CHEST. Elevator accident; rupture of diaphragm and hernia of stomach and spleen; no hæmorrhage; arteriosclerosis; atheroma of pulmonary artery; œdema of lungs; fracture of ribs; interstitial nephritis.

83 (Johnston)—Male, 22. Nov. 18, 1895. Dr. Molson.

HÆMORRHAGE INTO RIGHT INTERNAL CAPSULE. Chronic interstitial nephritis; hypertrophy and dilatation of heart; atheroma of arteries; arterio sclerosis; ecchymosis of stomach; sclerosis of pulmonary arteries; granular pharyngitis; pulmonary apoplexy.

84 (Johnston)—Male, 16. Nov. 20, 1895. Dr. Armstrong.

CRUSH OF CHEST AND ABDOMEN. Rupture of spleen and displacement of fragments; fracture of left femur; separation of epiphysis of left tibia; greenstick fracture of left ulna; multiple contusions; hæmorrhage into peritoneum; two accessory spleens; functional hypertrophy of heart; ecchymosis of pelvis of kidneys; congestion and ecchymosis of lungs.

85 (Johnston)—Male, 50. Nov. 22, 1895. Dr. Molson.

PARIS GREEN POISONING. Sesquioxide of iron in bronchi; sclerosis of tricuspid and mitral valves; brown atrophy of heart; arterio sclerosis; brown ecchymosis beneath pleura; ecchymosis of spleen; acute catarrhal gastritis with œdema and ecchymosis; œdema of intestinal mucosa; absence of fœtor; Paris green in stomach and intestines; chronic interstitial nephritis with cyst; slight fibrous epididymitis; hypertrophy of lateral lobes of prostate: slight fatty and cirrhotic liver.

86 (Johnston)—Female, 72. Nov. 25, 1895. Dr. Finley.

THROMBOSIS OF LEFT SYLVIAN ARTERY. White softening of brain; arterio sclerosis; anasarca; chondromalacia; hypertrophy, dilatation and brown atrophy of heart; sclerosis of endocardium and coronaries; subendocardial lipoma; chronic bronchitis; indurative peribronchitis; acute capillary bronchitis and broncho-pneumonia; chronic interstitial nephritis; pneumococcus infection.

87 (Johnston)—Male, 21. November 28th, 1895. Dr. Finley.

CHRONIC TUBERCULOUS PERITONITIS. PERFORATIVE APPENDICITIS. Tuberculous meningitis; left sero-fibrinous pleurisy; right dry tuberculous pleurisy; atrophy of heart; miliary tuberculosis of spleen, liver and kidneys; chronic catarrhal gastritis; recent softening of fornix; intestine free from tuberculosis. Mania.

88 (Johnston)—Male, 17. November 30th, 1895. Dr. Kirkpatrick.

RUPTURE OF LIVER. Hæmorrhage into peritoneum from branch of portal vein; acute emphysema and pulmonary apoplexy; food in bronchi; persistence of thymus gland.

89 (Jamieson)—Male, 25. December 1st, 1895. Dr. Molson.

CHRONIC ULCERATIVE PHTHISIS. Milk patch of heart; hypertrophy of heart; arteriosclerosis; aortic incompetence; aortic and mitral sclerotic endocarditis; nutmeg liver.

90 (Johnston)—Female, 4. December 3rd, 1895. Dr. Kirkpatrick.

BURN OF SKIN. Retro peritoneal hernia.

91 (Johnston)—Male, 33. December 3rd, 1895. Dr. Finley.

HYPERTROPHIC BILIARY CIRRHOSIS OF LIVER. Jaundice ; enlargement of spleen, 1930 grams ; anasarca ; chronic adhesive peritonitis ; dilatation of collateral veins ; slight thickening of heart valves ; subacute parenchymatous nephritis ; slaty pigmentation of rectum ; corpora amylacea of prostate ; follicular ulceration of ileum ; slaty pigmentation of solitary follicles.

92 (Johnston)—Male, 30. December 30th, 1895. Dr. Shepherd.

TUBERCULOUS PYELONEPHROSIS. Tuberculosis R. ureter. Nephrotomy Caseous tuberculosis of R. testicle, and miliary tuberculosis of L. testicle ; general acute miliary tuberculosis ; tuberculous meningitis ; bony anchylosis of both knees and right hip ; tuberculous sinus in right flank following nephrotomy localized miliary tuberculosis of peritoneum ; false diverticula coli ; slight mitral sclerosis ; brown atrophy of heart ; subpleural ecchymosis ; miliary tubercles in spleen, liver and kidneys.

93 (Johnston)—Male, 22. Dec. 7, 1895. Dr. Finley.

TYPHOID FEVER. Ecchymosis of mucosa of gall bladder ; local acute simple peritonitis ; staphylococcus aureus infection ; slight atheroma of mitral and aortic valves ; slight atheroma of coronaries ; acute bronchitis ; acute hyperplasia of spleen ; cloudy swelling of kidneys and liver ; typhoid ulceration of ileum and colon with adherent sloughs ; acute hyperplasia of mesenteric glands. Typhoid culture from spleen.

94 (Johnston)—Male, 28. Dec. 11, 1895. Dr. Molson.

CHRONIC SUPPURATIVE PYELONEPHRITIS. Calcified thrombus in pulmonary artery ; abscess of pancreas ; suppurative perinephritis ; psoas abscess ; general amyloid ; bifid cartilage of 3rd rib ; bedsores ; left pyelonephrosis (early) ; amyloid of kidneys, spleen, liver, adrenals, intestines, bladder, stomach and gallbladder; lacteal cysts in wall of intestines; amyloid of pancreas ; calcification of mesenteric arteries ; brown atrophy of heart ; black pigmentation of pia ; B. coli infection.

95 (Johnston)—Female, 14. Dec. 11, 1895. Dr. Kirkpatrick.

ACUTE SEPTIC FIBRINO-PURULENT PERITONITIS. Menstruation ; laparotomy ; corpus luteum ; hyperæmia of lung ; streptococcus infection ; (history of sore throat) ; no local cause..

96 (Johnston)—Male, 63. Dec. 16, 1895. Drs. Molson and Wilkins.

CHRONIC TUBERCULOUS FIBRO-CASEOUS PERICARDITIS. Chronic tuberculous peritonitis ; tuberculous pleurisy with effusion ; chronic bronchitis ; collapse induration of lung ; chronic catarrhal gastritis ; villous papilloma of stomach ; caseous tubercle mesenteric glands ; tubercles in capsule of spleen ; slight chronic interstitial nephritis ; enlarged prostate ; corpora amylacea ; nutmeg liver ; accessory thyroid calcareous plates in dura.

97 (Jamieson)—Female, 60. Dec. 19, 1895. Dr. Alloway.

COLLOID ADENOCARCINOMA OF SIGMOID FLEXURE. Acute septic peritonitis; secondary colloid cancer of omentum and peritoneum; laparotomy; chronic glomerulo-nephritis; myomata and secondary cancer of uterus; cystic ovaritis with hæmatoma.

98 (Jamieson)—Male, 23. Dec. 19, 1895. Dr. Molson.

CHRONIC PHTHISIS WITH CAVITIES. Hydropericardium; milk patches.

99 (Jamieson)—Male, 36. Dec. 22, 1895. Dr. Armstrong.

CRUSH OF R. LEG. Railway accident. Hæmorrhage; amputation; obsolete tubercles in lungs; slight emphysema; thickening of edges of aortic and mitral valves; atheroma of aorta.

NUMBER OF AUTOPSIES RECORDED.	1883	1884	1885	1886	1887	1888	1889	1890	1891	1892	1893	1894	1895	Average.
Total in each year	80	47	67	74	96	90	75	69	49	61	66	46	101	71·7
Private cases	9	0	3	10	9	4	8	10	0	6	0	0	0	....
Hospital cases...	71	47	64	77	87	86	67	59	49	55	66	64	101	67·3
Total deaths in hospitals	144	143	162	154	185	196	183	169	159	189	213	191	174	174
Percentage autopsies to death ..	49·3	32·8	38·8	50·0	47·5	43·8	36·6	34·9	30·8	29·1	30·9	33 5	58·0	39·6

Number recorded by Osler, 87; Sutherland, 45; Howard, 32; Jamieson, 4; Johnston, 457; Latleur, 87; Finley, 107; Adami, 73; Martin, 4; Williams, 35 others, 3.

SPECIAL INDEX.

GENERAL LESIONS AND DISTURBANCES.

ANOMALIES—(Also see organs).

Bifid ribs, **85**, 838 ; **95**, 94 2
Diverticulum of bladder, **83**, 723 ; **86**, 19 2
Horseshoe kidney, **84**, 883 1
Uterus bicornus, **85**, 836, 850 2
Persistent foramen ovale, **83**, 743 ; **89**, 49 ; **90**, 29 ; **93**, 21 ; **94**, 18 5
Lungs, abnormal lobulation, **85**, 872, 61 ; **93**, 38 3
Meckel's diverticulum, **85**, 872, 885 ; **86**, 63 ; **87**, 21 4
Open tunica vaginalis, **91**, 46 1
Retroperitoneal hernia, **95**, 90 ... 1
Bifid uvula, **80**, 783 1
Dextroposition of rectum, **86**, 15, 47 ; **90**, 54 3
Liver, elongation left lobe, **83**, 708, 731, 739 ; **85**, 856, 876 ; **86**, 9; **87**, 4 ; **90**, 57 8
—Liebermeister furrows, **83**, 701, 761 ; **87**, 49 ; **90**, 25, 67 5
Accessory spleen, **83**, 747 ; **84**, 783 ; **87**, 94, 95 ; **89**, 53 ; **93**, 22. 6

DISTURBANCES OF CIRCULATION—(See under organs of circulation).

INFLAMMATIONS, INFECTIONS AND SPECIFIC DISEASES.

Septichæmia, **85**, 856 ; **86**, 61 ; **87**, 2, 13, 15, 19 ; **93**, 26 ; **94**, 15 ; **95**, 8 9
Pyæmia, **83**, 708, 717 ; **84**, 781 ; **85**, 817, 818, 850, 886 ; **86**, 9, 23, 58, 85 ; **87**, 2, 74, 86 ; **88**, 14, 50 ; **89**, 7, 14, 38 ; **90**, 13, 15 ; **91**, 42 ; **92**, 21, 51 21

INFECTIONS—(Only unusual or specially well marked cases).

Pyogenic cocci.
S. P. Aureus, **92**, 23 ; **95**, 52, 93... 3
Streptococcus, **86**, 31 ; **87**, 2, 13, 15, 19 ; **90**, 15 ; **93**, 31 ; **94**, 7 ; 10 ; **95**, 19, 22, 46, 47, 73, 75, 94, 95. 17
Pneumococcus, **94**, 13 ; **95**, 5, 24, 35 4
Other infections, **85**, 846, 851 ; **87**, 42 ; **88**, 37, 66 5

LOCAL SUPPURATION AND ABSCESS—

Face, **87**, 56 1
Cranium, **90**, 26 1
Brain, **86**, 68 ; **88**, 6 ; **89**, 40 ; **92**, 23 ; **93**, 64 ; **94**, 13 6
Meningeal, **94**, 30 ; **91**, 35, 39, 48. 4
Parotid, **86**, 57 1
Antrum, **90**, 26 1
Frontal sinus, **88**, 6 1
Cerebellum, **85**, 835 1
Inguinal glands, **85**, 856 1
Cervical glands, **92**, 25 ; **93**, 30*a* ; **95**, 65 ; **90**, 16 4
Pleura, **87**, 29, 55, 79 3
Muscles, Pectoral, **88**, 14, 56 ; **90**, 9. 3
—abdominal, **93**, 41 1
—psoas, **85**, 822 ; **88**, 5, 11 ; **92**, 37 ; **93**, 45 ; **95**, 94 6

IMAGE EVALUATION
TEST TARGET (MT-3)

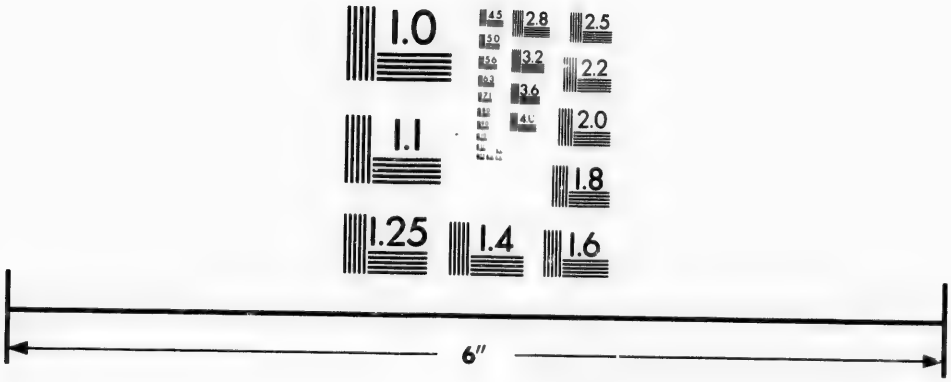

Photographic
Sciences
Corporation

23 WEST MAIN STREET
WEBSTER, N.Y. 14580
(716) 872-4503

2.8
2.5
3.2
3.6
2.2
2.0
1.8
1.1
1.0

Abcess.

Præ-vertebral, **86**, 52; **95**, 49, 77. 3
Retro-pharyngeal, **85**, 840; **89**, 14; **90**, 24 3
Limbs and joints, **84**, 781, 806; **87**, 36, 74; **95**, 12, 46; **86**, 15; **88**, 21; **89**, 68; **93**, 26..... 10
Kidney, **92**, 38, 44, 51; **89**, 2..... 4
Perinephritic, **87**, 54, 51; **93**, 25; **95**, 94 3
Splenic, **87**, 57; **90**, 23 2
Pancreatic, **88**, 79 1
Perityphilitic (see also appendicitis), **88**, 33, 50..... 2
Prostatic, **85**, 817; **86**, 85; **90**, 2. 3
Vesical, **90**, 40 1
Perineal, **86** 58..... 1
Pelvic, **84**, 781; **85**, 825; **92**, 47; **87**, 52..... 4
Ischiorectal, **86**, 9..... 1
Uterine, **92**, 59 1
Broad ligament, **89**, 7..... 1
Ovarian **85**, 846 1
Liver, **84**, 809; **85**, 824; **86**, 20; **88**, 39; **89**, 36; **92**, 24, 26; **95**, 7, 10 9
Gall-bladder, **90**, 19..... 1
Omphalophlebitis, **92**, 21 1
Subdiaphragmatic, **93**, 51 1
Vulvar, **87**, 38 1
Other, **87**, 9; **89**, 64; **90**, 40, 53. . 4
Ulcers and Sinuses, **89**, 3; **90**, 14; **93**, 32..... 3
Bed Sores, (see skin)..... 1
Anal Fistulae, **86**, 17, 70; **87**, 5, 42. 87; **89** 60 6
Purulent Otitis, **87**, 71; **88**, 1; **89**, 53; **90**, 17; **91**, 44 5
—pericarditis, **91**, 31..... 1
—peritonitis (see also peritoneum), **87**, 90; **93**, 66; **91**, 40..... 3
Laryngeal (see also larynx), **93**, 50; 30*a*, 31 3

GENERAL AND SPECIFIC INFECTIONS—

Erysipelas, **83**, 769; **85**, 828; **86**, 15; **92**, 56; **95**, 43; **95**, 46..... 6

Tuberculosis.

Puerperal fever, **86**, 18, 30, 31; **87**, 2, 13, 15, 19; **93**, 54; **95**, 75 9
Influenza, **90**, 7; **95**, 5..... 2
Gonorrhœa, **89**, 73; **90**, 17, 64.... 5
Syphilis, **83**, 773, 774; **84**, 781; **85**, 840, 843, 846, 881; **87**, 17, 80; **88**, 3, 22, 51, 65; **89**, 5, 20, 35; **90**, 54; **91**, 42; **92**, 32; **93**, 20, 52 **94**, 26; **95**, 71..... 23
Glanders, **85**, 848 1
Tetanus, **84**, 806; **91**, 47 2
Acute Cerebro-spinal Meningitis (fever), **88**, 33 1
Typhoid Fever, **83**, 749, 750, 758, 763, 767, 779; **84**, 807, 812; **85** 851*a*, 853, 858, 862, 878, 887; **86**, 2, 55, 82; **87**, 53, 57, 58, 62, 68, 71, 72, 73, 76; **88**, 67; **89**, 26, 32, 33, 39, 49, 64 **90**, 47; **92**, 28, 51; **93** 9; **94**, 4, 38, 39; **95**, 53, 62, 69, 2, 90, 93 46
Diphtheria, **83**, 707, 711, 715, 733, 763, **84**, 783, 794, 799; **85**, 832; **86**, 45, 82; **87**, 31*a*, 46, 66, 78, 92, 94, 95; **88**, 4, 15, 24, 29, 30, 31, 55, 86; **89**, 57, 71; **91**, 41; **92**, 41, 56, 57; **93**, 61; **94**, 3; **95**, 65... 35
Scarlatina, **83**, 740; **92**, 56; **93**, 30*a*, 50, 52 5
Purpura, **88**, 63..... 1
Purpura new-born, **86**, 61..... 1

TUBERCULOSIS—

Tuberculosis (general miliary), **83**, 709, 746, 754, 713, 774; **84**, 782, 783, 792; **85**, 870, 879, 825, 874, 882; **86**, 12, 34, 73, 35, 38, 41; **87**, 3, 5, 69, 79, 81; **88**, 1, 27, 17, 35. 15, 5; **89**, 27; **90**, 29, 40, 41, 9, 38, 31; **91**, 34; **92**, 37, 43; **93**, 19, 36, 23, 43, 45; **94**, 13, 20, 28, 34; **95**, 37, 48, 49, 44, 6, 28, 29, 30, 54, 77, 87.....
—of lungs, severe, **83**, 701, 706, 710, 713, 724, 726, 730, 731, 734, 738, 741, 744, 709, 746, 754, 766, 768; **84**, 782; **85**, 820, 825, 829, 837, 838, 859, 874, 879, 880, 883 **86**,

4, 12, 28, 34, 35, 36, 38, 39, 41, 42, 50, 52, 56, 70, 73, 75, 79, 84; **7**, 3, 5, 11, 12, 16, 30, 31, 34, 37, 38, 39, 43, 47, 51, 55, 61, 69, 77, 79, 81, 82, 93; **88**, 1, 5, 11, 17, 27, 28, 35, 36, 47, 49, 52, 78; **9**, 3, 17, 21, 41, 61, 66; **90**, 5, 9, 12, 24, 31, 38, 40, 41, 58, 62; **92**, 29, 34, 37, 43, 46, 48, 50; **93**, 19, 20, 23, 45, 33, 36, 40, 43, 49, 56; **94**, 3, 6, 13, 17, 20, 21, 23, 28, 40, 42; **95**, 6, 28, 29, 30, 34, 43, 48, 49, 54, 64, 80, 87, 92, 96, 98 137

—of lungs, slight or obsolete-apical, **83**, 714, 732, 733, 767; **85**, 826, 865, 866, 885, 886; **86**, 24, 46, 55; **86**, 7, 73, 84; **88**, 60, 79, 88; **89**, 1, 11, 15, 16, 32, 37, 50, 65; **90**, 48; **91**, 29, 34; **92**, 56; **93**, 28, 54, 60; **94**, 21, 21*a*, 25, 40; **95**, 20, 21, 22, 27, 37, 45, 53, 89, 99 46

Pericardium, **85**, 859; **86**, 55 2

Heart muscle, **90**, 41 1

Retro-pharyngeal, **90**, 24 1

Cervical, **87**, 73 1

Pleura (see pleura) 95

Thoracic duct, **87**, 12; **95**, 28 2

Larynx, **85**, 828, 837; **86**, 39, 42, 52; **87**, 16, 34, 38, 47, 51, 93; **88**, 5, 27; **89**, 17, 41; **90**, 29, 40 **93**, 54; **94**, 21; **95**, 80 20

Pharynx, **87**, 37 1

Stomach, **88**, 28 1

Intestine, **83**, 709, 730, 731, 734, 738, 741; **84**, 783; **85**, 870, 882; **86**, 12, 34, 26, 38, 39, 41, 42, 52, 55, 73, 75, 79; **87**, 3, 5, 11, 16, 34, 39, 47, 51, 77, 82, 84, 93; **88**, 27, 47, 49, 78; **89**, 17, 41, 68; **90**, 29, 40; **92**, 34, 46, 48; **93**, 20, 36, 56, 80; **94**, 20, 23, 40, 45; **95**, 44, 64, 80 .....

Liver, **83**, 754; **84**, 782, 783; **85**, 825, 870, 874, 879; **86**, 12, 73; **87**, 3, 5, 69, 79, 81; **88**, 15, 27; **90**, 29, 36, 40, 41; **92**, 37, 43; **93**, 19, 23, 36, 40; **95**, 44, 49, 54 29

Tuberculosis.

Peritoneum, **83**, 730, 766; **84**, 782, 798; **85**, 825; **86**, 7, 9, 12, 35, 50; **87**, 3, 39, 81; **88**, 1; **89**, 66; **90**, 24, 31; **92**, 34; **95**, 35, 77, 87, 92, 96 23

—spleen, **83**, 709, 754; **84**, 782, 783; **85**, 870, 879; **86**, 12; **87**, 5; **88**, 1, 27; **90**, 29, 40, 41; **92**, 37; **93**, 19, 36,; **95**, 37, 48, 49, 87, 92 20

Kidney (pyelitis), **83**, 754; **85**, 859; **86**, 28, 70; **87**, 58; **88**, 36; **89**, 11; **95**, 82 8

Kidney (mil. tub.), **83**, 713, 774; **84**, 782, 783; **85**, 825, 870, 879, 882; **86**, 12, 35, 38, 41, 73; **87**, 3, 5, 69, 79, 81; **88**, 1, 5, 27; **90**, 29; **92**, 37, 43; **93**, 23; **94**, 34; **95**, 28, 49, 54, 87 30

Ureter, **95**, 92 1

Bladder, **83**, 754, 759; **86**, 28; **87**, 81; **90**, 40 5

Urethra, **87**, 5, 81: **90**, 6 3

Prostate, **86**, 70; **92**, 29 2

Seminal vesicles, **86**, 28 1

Testes, **85**, 822; **86**, 70; **87**, 5; **92**, 29; **95**, 92 5

Vagina, **83**, 719 1

Uterus, **84**, 20 1

Fallopian tubes, **85**, 825; **86**, 35; **92**, 34; **95**, 64 4

Pia, **83**, 746; **84**, 782, 792; **86**, 12, 34; **87**, 3, 5, 81; **88**, 1, 17, 35; **90**, 9, 38; **91**, 34; **92**, 37, 43; **93**, 19, 23, 36, 43, 45; **94**, 13, 20, 28; **95**, 6, 28, 29, 30, 54, 77, 87, 92 .. 31

Solitary (brain), **87**, 3; **90**, 9; **91**, 34; **93**, 40, 43; **95**, 29 6

TUBERCULOSIS PRIMARY LESION, NON-PULMONARY—

Bones, **83**, 714; **85**, 820, 882; **87**, 8; **92**, 37, 43; **93**, 45; **94**, 17; **95**, 49, 77 10

Vagina, **83**, 709 1

Mesenteric, **83**, 710; **86**, 38; **87**, 84; **92**, 46; **93**, 19, 54; **95**, 22, 29, 72, 96 10

Tuberculosis.

Spinal, **88**, 32 1
Lupus, **92**, 46 1
Tongue, **88**, 52 1
Œsophagus, **83**, 60 1
Infection by wound, **88**, 28 1
Joints, **87**, 79; **85**, 34, 35; **95**, 45. 4
Skin, **88**, 20 1

ANIMAL PARASITES.

Malaria, **85**, 863 1
Trichinosis, **89**, 5, 30 2
Amœba coli (see also under dysentery and abscess of liver), **85**, 824; **86**, 36; **94**, 21*a* 3
Ascarides, **87**, 33, 70; **88**, 26, 30; **95**, 72, 80 6
Phthiariasis, **86**, 16; **95**, 96. ... 2

GENERAL AND FUNCTIONAL DISEASES.

Diabetes mellitus, **90**, 2, 58, 59; **92**, 53 4
Acetonuria, **90**, 58, 59 2
Uræmia, **83**, 727, 723; **87**, 23; **89**, 5, 75 5
Toxæmia, **89**, 73 1
Eclampsia, **87**, 45; **94**, 21*a* 2
Epilepsy (see nervous system) ....
Chorea major, **87**, 14 1
Acute Rheumatism, **86**, 1; **89**, 69; **95**, 8 3
Gout, **89**, 49 3
Rheumatoid arthritis, (see under joints) .....
Rickets, (see under bones) .....
Marasmus infantile, **89**, 44, 45, 56; **93**, 32 4
Marasmus senile, **92**, 49 1
Addison's disease, see also under adrenals, **85**, 863, 865 2

TUMOURS—

Benign Tumours.

Deciduoma, **88**, 49 1
Hypertrophy (compensatory) of kidney, **85**, 836; **91**, 29 2

Tumours.

—of prostate, **86**, 5, 7, 9, 17, 81, 85; **87**, 32, 70; **88**, 7, 37; **90**, 67; **92**, 38 12
Osteoma (exostosis) **89**, 68; **93**, 16; **95**, 49 3
Angioma of liver, **87**, 45, 68, 82, 89; **89**, 15; **90**, 10, 25; **91**, 43; **94**, 39 9
Lymphoma, **83**, 704 1
Lipoma (rectum), **93**, 55 1
Glioma (brain), **92**, 49; **93**, 17 2
Fibroma of kidney, **87**, 4 1
Fibro-myoma of uterus, **83**, 702, 712, 739; **85**, 836, 860, 864; **86**, 43; **87**, 67; **88**, 40, 63; **89**, 1, 57; **90**, 14; **92**, 39, 49; **93**, 37; **94**, 32; **95**, 5, 17, 45, 97, ... 23
Condyloma of penis, **87**, 36. 1
—of vulva, **94**, 21*a* 1
Adenoma (papillomatous) of stomach, **95**, 66, 96 2
—polypoid of rectum, **87**, 63 1
—polypoid duodenum, **86**, 38 1
—of kidney, **90**, 51 1
—adrenal in kidney, **87**, 73; **90**, 51; **95**, 81 3
—sebaceous glands, **92**, 29 1
Adeno-cystoma of ovary, **86**, 71; **87**, 3; **88**, 40; **89**, 62; **90**, 37, 51; **91**, 34; **95**, 22 8
—of ovary, papillomatous, **83**, 745; **95**, 78 2
—of ovary, dermoid, **94**, 24 1
Parovarian cyst, **83**, 767 **85**; , 831; **89**, 14; **95**, 54 4
Cyst of fallopian tube, **90**, 37 1
Cyst of epididymis, **90**, 40 1
Cystic bronchocele (see goitre) **83**, 702; **88**, 16 2
Congenital cysts of liver, **88**, 21... 1

Malignant Tumours—

CANCER—

Epithelioma (primary), penis, **83**, 762; **95**, 68*a* 2
—tongue, **90**, 52 1
—scalp, **93**, 46 1
—œsophagus, **86**, 6; **87**, 35; **91**, 43; **93**, 51, ... 4

Cancer.

—bladder, **95**, 74 1
—(Secondary).
— inguinal glands, **88**, 762 1
—lungs, liver, vena cava, heart, duodenum and retro-peritoneal glands, **95**, 74 1
—bronchial glands, trachea, **87**, 35 1
—lungs, **90**, 52 1

CARCINOMA (Primary).

Mamma, **87**, 1; **91**, 40*a* 2
Stomach, **83**, 745; **85**, 823; **86**, 16, 66, 72, 76; **87**, 8; **88**, 13; **89**, 15, 48, 67; **90**, 23, 53; **92**, 35 14
Intestine, **86**, 27. **89**, 9, 11, 15, 30; **90**, 31; **95**, 97; (colloid) ileum, **91**, 20 8
Rectum, **85**, 834; **86**, 56 (colloid); **88**, 69; **94**, 31 4
Uterus, **83**, 719; **90**, 31; **95**, 31 ... 3
Kidney **85**, 869; **93**, 42 2
Bladder, **90**, 20; colloid 1
Prostate, **93**, 11 1
Liver, **83**, 759; **84**, 788; **92**, 33 ... 3
Lung, **93**, 48 1
Pancreas, **83**, 737; **86**, 27 2

CARCINOMA (Secondary).

Liver, **89**, 27; **87**, 1, 8; **88** 13, 16; **89**, 11, 15, 30, 48, 67; **90**, 31; **91**, 40*a*, 43; **92**, 33, 35; **93**, 42, 48 ... 17
Lungs, **83**, 737, 759; **86**, 27, 43; **87**, 1 5
Bladder, **83**, 719; **93**, 11; **95**, 31 .. 3
Kidney, **86**, 27; **89**, 56 2
Muscle, **89**, 9 1
Adrenal, **95**, 74 1
Bone marrow, **87**, 8 1
Bones, **91**, 40*a* 1
Peritoneum, **89**, 67 1
Mesentery, **91**, 43 1
Omentum, **85**, 868; **87**, 8; **91**, 43; **95**, 97 4
Pleura, **91**, 40*a* 1
Pancreas, **85**, 823 1
Rectum, **83**, 719; **90**, 31 2
Stomach, **93**, 5 1
Uterus, **95**, 97 1

Bronchial glands, **93**, 48 1
Mediastinal glands, **89**, 56; **92**, 33 .....
Inguinal, **88**, 69; **93**, 11 2
Portal glands, **90**, 23; **92**, 33 2
Pelvic " **90**, 20 1
Retro-peritoneal, **85**, 868; **87**, 8; **89**, 11, 67: **92**, 11, 33, 42; **95**, 31. 8
Subclavian vein, **87**, 1 1
Iliac artery, **93**, 11 1

SARCOMA—

Lymphosarcoma (lung and pleura), **86**, 48, (bronchial gland) **94**, 29. 2
Fibro sarcoma (skin), **90**, 48 1
Osteo sarcoma (leg, secondary in lungs and pleura), **85**, 840*a*; frontal bone, **95**, 59 2
Sarcoma lipomatodes, peritoneum, **93**, 58 1
Melanotic (skin), **89**, 60; **94**, 51 .. 2
Alveolar, **83**, 718; vertebra, **88**, 43 2
Small spindle celled, **90**, 57 1
Glio sarcoma (brain), **83**, 720; **86**, 29; **87**, 23; **90**, 34; **91**, 45 .. 5
Cysto sarcoma (ovary), **85**, 854 ... 1
Angio sarcoma (brain), **89**, 25 1

DEGENERATIONS—

Necroses (see under organs).

AMYLOID—

Amyloid kidney, **83**, 717, 747, 760; **85**, 820, 840, 847; **86**, 4, 39, 42, 70 79, 84; **87**, 34, 39, 47, 87, 82; **88**, 65; **89**, 34; **90**, 29, 54, 62; **93**, 49, 60: **95**, 41, 94 26
—bladder, **87**, 39; **90**, 27; **95**, 94, 3
—spleen, **83**, 714, 747, 760; **85**, 820, 829, 847; **86**, 4, 39, 42, 43. (Bacon), 70, 79, 84; **87**, 34, 39, 47, 79, 81, 82, 93, 88, 13, 65; **89**, 34; **90**, 62; **95**, 94 26
—pancreas, **90**, 29 1
—liver, **83**, 747, 760, 820; **85**, 820, 840, 847; **86**, 42, 70, 79; **87**, 34, 39, 47, 81, 82; **88**, 13, 65; **89**, 34; **90**, 29, 62; **94**, 45; **95**, 94 21

Amyloid.
Gall-bladder, **95**, 94 1
Intestine, **86**, 39, 42, 70, 84 ; **87**, 34, 39, 47, 82, 93 ; **88**, 13 ; **89**, 34 ; **93**, 60 ; **95**, 94 13
Stomach **87**, 39 ; **90**, 29 ; **95**, 94. 3
Adrenal, **95**, 94 1
CALCIFIED PLATES OR NODULES.
—brain, **86**, 78 1
—liver, **94**, 10, 39 2
—lung (see lungs). .....
—pleura, **92**, 27 1
—uterus, **95**, 78 1
—ovaries, **93**, 34 .....
—corpora amylacea, **95**, 91. (See prostate) .....
Hyaline degeneration, spleen, liver and kidneys, **86**, 36 1
Fat necrosis omentum, **87**, 75 1
Melanotic pigmentation, **93**, 37 .. 1
CALCULI—
Renal, **83**, 760 ; **84**, 804 ; **86**, 11, 17 ; **87**, 28 ; **93**, 61, 64 7
Vesical, **88**, 58 ; **93**, 18 2
Ureter, **93**, 25 1
Prostate, **87**, 89 ; **89**, 35 2
Gall stones, **89**, 6, 20 ; **91**, 42 ; **92**, 24, 36, 45 ; **95**, 57, 76 8
Tophi, **89**, 47 1
For other degeneration see under organs.

INJURIES.

FRACTURES (see under bones).
DISLOCATION (see under joints).
Hæmorrhage longitudinal sinus at birth, **88**, 12 1
Instrumental abortion, **86**, 57 ... 1
Bullet wounds (abdomen), **85**, 851*b* 1
—head, **86**, 12 ; **88**, 64 ; **89**, 32 ; **95**, 49, 63 5
Foreign body foot (tetanus), **84**, 806 1
Concussion of brain, **83**, 752 1
Burns, **84**, 811 ; **95**, 90 2
Rupture of pancreas, **85**, 871 1
—of diaphragm, **95**, 84 1
—rupture of spleen, **83**, 757 ; **85**, 871 ; **95**, 36, 40 1

Injuries.
—rupture of kidney, **83**, 757 ; **85**, 871 4
—rupture intestine, **89**, 13, 51 2
—of liver, **95**, 38, 88 .....
Laceration of skin and muscle, **87**, 20 ; **95**, 38 ; **94**, 43 3
—laceration of heart, **95**, 40 1
—laceration of pleura, **87**, 20 1
—spinal cord, **89**, 55 1
—urethra **86**, 51, 58 ; **89**, 73 3
—laceration of ureter in forceps labour, **87**, 54 1
Passage of bougie into lung, **86**, 6. 1
—peritoneum, **85**, 843 ; **94**, 22 1

OPERATIONS—
Laparotomy, **85**, 825 ; **87**, 13 ; **92**, 47 ; **93**, 66 ; **94**, 33 ; **95**, 7, 22, 47, 48, 73, 81, 95, 97 13
Colotomy, **94**, 31 1
Suture of intestines, **95**, 69 1
Resection of intestines, **95**, 42, 68. 1
Castration, **87**, 5, **95**, 12 2
Amputation of breast, **86**, 43 1
—foot, **85**, 879 1
—thigh or leg, **83**, 769 ; **85**, 840*a* ; **88**, 14 ; **91**, 47 ; **94**, 34 5
—of tongue, **88**, 52 ; **90**, 52 2
—of labia minora, elephantiasis, **84**, 781 1
Excision of knee, **85**, 886 1
Cystotomy, **90**, 20 ; **93**, 18 ; **95**, 74. 3
Hysterectomy, **90**, 57 1
Radical hernia, **88**, 60 ; **91**, 8 ; **93**, 32 3
Laminectomy, **89**, 55 1
Nephro lithotomy, **87**, 10 ; **90**, 42 ; **95**, 92 3
Nephrectomy, **90**, 33 1
Ovarectomy, **95**, 78 1
Lithotomy perineal, **86**, 17, 70 2
Opening sub-diaphragmatic abscess, **94**, 7 1
Puncture of pericardium, wound of coronary vein, **94**, 41 1
Suture of patella, **88**, 21 1
Intubation, **88**, 4, 15, 30 3

Tracheotomy, **83**, 707, 751 ; **84**, 794 ; **86**, 45 ; **87**, 94 ; **88**, 24 ; **95**, 65 7
Thoracocentesis, **89**, 27..... 1
Trephining skull, **87**, 27 ; **93**, 64 ; **95**, 63 3
Trephining mastoid, **95**, 10 1
Venesection, **83**, 753, 755 ; **91**, 4.. 3

POISONS—

Arsenic (rough on rats), **87**, 60, 80. 2
(Paris Green) **95**, 85 1
Chlorate of potassium **85**, 856....
Potassium bichromate, **88**, 38.... 1
Carbolic acid, **89**, 8 ; **95**, 32 2
Laudanum, **95**, 33 1
Ptomaine poisoning, **89**, 37..... 1
Alcoholism, **86**, 8, 40, 37, 52, 69 ; **87**, 7, 22 ; **89**, 5, 20 ; **93**, 30 ; **95**, 61, 76 12
Plumbism, **95**, 61..... 1
Sunstroke, **89**, 29..... 1
Sudden death, causes not detected, **85**, 866, 881 ; **86**, 9, 10, 30 ; **87**, 91 6

Diseases of new born infants, **85**, 868 ; **86**, 10, 59, 61 3

HOMICIDE—

Criminal abortion, **86**, 57..... 1
Rupture of ileum from blow, **89**, 13..... 1

SUICIDE—

Firearms, **86**, 14 ; **88**, 64 ; **90**, 26 ; **95**, 63..... 4
—Poison, Arsenic, **87**, 60, 80..... 2
—Carbolic acid, **89**, 8 ; **95**, 32..... 2
—Potassium Bichromate, **88**, 38.. 1
—Laudanum..... 1

ARTEFACTS—

P.M. invagination of intestine, **83**, 792 ; **87**, 31*a*, 58 ; **95**, 57.... 4
P.M. digestion œsophagus, **89**, 17. 1
—stomach, **95**, 18, 50, 87 3
P.M. digestion lung, **95**, 87 1

CIRCULATORY SYSTEM.

BLOOD—

Anæmia, simple, **85**, 863, 866 ; **86**, 17, 25 ; **87**, 17, 25 ; **89**, 53, 61 ; **90**, 22 ; **92**, 42 ; **95**. 17, 19..... 12
—secondary, **88**, 14, 78 ; **90**, 51 ... 3
—pernicious, **83**, 739, 748 ; **84**, 793, 801 ; **90**, 68 ; **93**, 12*a* ; **95**, 66 .. 7
Leuchæmia, **83**, 704 ; **94**, 1..... 2
Purpura, **86**, 59, 61 ; **94**, 4, 5..... 4
Multiple ecchymoses, **88**, 63 ; **94**, 21*a* 2
Methæmoglobinæmia, **85**, 856 ; **88**, 38..... 2
Fluidity of blood (sunstroke), **89**, 29 1

HÆMORRHAGE—

Pericardium, **83**, 725 ; **87**, 87 ; **94**, 41 ; **95** ,57 4
Pleura, **85**, 826 ; **87**, 21 ; **95**, 39, 54, 56, 68..... 6
Peritoneum, **83**, 765 ; **85**, 851*b* ; **92**, 54 ; **95**, 36, 84, 88 6
Pelvic hæmatoma, **89**, 66..... 1
Hæmoptysis, **83**, 710 ; **90**, 48..... 2
Pulmonary apoplexy, **87**, 6, 36, 89 3
Epistaxis, **88**, 29 1
Œsophagus, **92**, 26..... 1
Stomach, **84**, 783 ; **89**, 6 ; **90**, 11 ; **94**, 1..... 4
Lesser omentum, **95**, 56 1
Pancreas, **92**, 61 1
From spleen, **88**, 26..... 1
From kidney (see kidney).....
Longitudinal sinus, **88**, 12..... 1

Hæmorrhage.

Meningeal, **83**, 756 ; **85**, 844 ; **86**, 12, 19, 14, 65 ; **87**, 65 ; **94**, 2..... 8

Cerebral, **83**, 703, 727, 728, 752; **85**, 836 ; **86**, 47, 54 ; **87**, 22 ; **88**, 2, 16, 25, 71 ; **90**, 10 ; **91**, 29 ; **92**, 20 ; **94**, 8 ; **95**, 56, 83 18

Secondary after operation, **88**, 14. 1

OEDEMA—

Anasarca, **83**, 716, 740, 776 ; **84**, 810 ; **85**, 821, 876 ; **86**, 5, 37, 63 ; **87**, 17, 25, 44, 63, 77, 84 ; **88**, 18, 19, 48, 57, 68 ; **89**, 5, 43, 70 ; **90**, 20, 60 ; **93**, 21, 37 ; **94**, 11, 37 ; **95**, 20, 25, 35, 49, 86, 91 35

Ascites, **83**, 716, 743 ; **85**, 821, 876, **86**, 37, 63 ; **87**, 25, 44, 77 ; **88**, 19, **89**, 4, 5, 43, 63, 67, 69, 70 ; **90**, 3 ; **94**, 11, 37 ; **95**, 25, 35, 71 23

Ascites chylous, **83**, 737 1

Hydrothorax, **83**, 740, 743 ; **84**, 810; **85**, 821 ; **86**, 5, 63 ; **87**, 42, 44, 63, 84 ; **90**, 3, 18, 20, 60 ; **91**, 32 ; **93**, 11, 16, 35, 55 ; **94**, 11, 18 ; **95**, 20, 25 23

Hydropericardium, **86**, 63 ; **88**, 57, **89**, 5 ; **90**, 20 ; **91**, 32 ; **93**, 55 ; **94**, 11 ; **95**, 20, 75, 98..... 10

VEINS—

Phlebitis septic jugular, **95**, 75... 1

—portal, **86**, 20 ; **95**, 73..... 2

—umbilical, **90**, 21 1

—other, **93**, 54 1

Obliteration of Hepatic, **86**, 9;

Vena cava sup., **86**, 83..... 1

" renal, **86**, 17..... 1

" jugular, innominate and vertebral, **89**, 70 1

Cancerous thromb. subclavian, **87**; 1, 20.....

Inf. cava and renal, **95**, 74..... 1

Wound of r. iliac vein, **85**; 851b, 1

Coronary, **94**, 41..... 1

THROMBOSIS—

Longitudinal sinus, **90**, 63..... 1

Lateral sinus, **87**, 88..... 1

Superior cava (see veins).....

Inferior cava, **95**, 74..... 1

Thrombosis.

Jugular V., **89**, 14, 70 ; **95**, 75 3

Sub-clavian V., **87**, 1 1

Pelvic V., **85**, 834 ; **87**, 52..... 2

Uterine V., **86**, 30 1

Iliac V., **85** 820 ; **89**, 9 ; **90**, 13 ; **91**, 38 ; **92**, 42 5

Femoral V., **89**, 69, 70 ; **90**, 14 ... 3

Saphena V., **85**, 826, 881 ; **90**, 14.. 3

Portal V., **83**, 704 ; **95**, 25, 73..... 3

Renal V., **83**, 745 ; **90**, 63 2

Coronary arteries, **85**, 881 ; **87**, 87 ; **92**, 39 3

Heart, **86**, 2 ; **89**, 60, 72 ; **90**, 18 (globular), 61 (polypoid) ; **95**, 11, 13 7

Cerebral arteries, **83**, 774 ; **86**, 78; **88**, 3, 16 ; **89**, 1..... 5

Hæmorrhoidal, **86**, 66; **87**, 38, 74.. 3

EMBOLISM—

Cerebral, **85**, 852 ; **86**, 43, 74 ; **93**, 47..... 4

Abdominal aorta, **90**, 18..... 1

Pulmonary, **85**, 866 ; **86**, 30 ; **89**, 69, 70 ; **92**, 42 ; **93**, 54 6

INFARCT—

Spleen, **83**, 708, 771, 779 ; **85**, 852, 856, 859 ; **86**, 11, 31 ; **87**, 29, 40, 41, 91 ; **88**, 16, 26 ; **89**, 7, 35, 53 ; **90**, 1, 18, 60 ; **93**, 47 ; **94**, 9, 11, 21 24

Kidney, **83**, 771, 776; **85**, 859 ; **86**, 2, 30, 43 ; **87**, 29, 41 ; **89**, 35 ; **90**, 18, 60 ; **91**, 38 ; **93**, 15, 46 ; **94**, 5, 21 16

Heart, **92**, 39 ; **93**, 15..... 2

Lung, **83**, 762 (cancerous), 778; **85**, 852 ; **86**, 23, 54 ; **88**, 21, 29 ; **89**, 35 ; **90**, 11 ; **94**, 5, 38 ; **95**, 31... 12

ARTERIES—

Endarteritis syphilitic, **83**, 774 ; **85**, 885 ; **94**, 26 ; **95**, 9..... 4

Endarteritis obliterans, **89**, 23 ; **90**, 28 (Hepatic) 2

Anomaly, renal, **90**, 14..... 1

Ligation, **94** ; (external iliac), 32.. 1

Arteries.

General arterio sclerosis, **83**, 755, 761, 767; **85**, 821; **86**, 7, 47, 63; **87**, 9, 23; **88**, 23, 71; **89**, 1, 23, 74; **90**, 10, 23, 25, 52, 57; **94**, 18, 55; **95**, 2, 8, 13, 21, 31, 43, 61, 71, 82, 83, 85, 86 32
Atheroma of aorta, **83**, 729, 739, 767; **84**, 787; **85**, 833, 852, 863; **86**, 15, 24, 37; **87**, 6, 12, 42, 65; **88**, 23, 51; **89**, 5, 19, 66; **90**, 25; **91**, 29; **92**, 22, 28, 30, 40, 44, 52; **93**, 11, 17, 20, 30, 34; **94**, 5, 19; **95**, 17, 20, 56, 68*a*, 72, 79, 99. 41
Atheroma of cerebral arteries, **83**, 722; **84**, 787, 800; **88**, 1; **93**, 11, 16, 22; **94**, 14, 21 9
Atheroma of coronary arteries, **83**, 722, 753; **84**, 787; **87**, 9, 74; **88**, 59; **92**, 22, 30, 39; **93**, 11, 16, 34; **95**, 39, 46, 66, 80, 86, 93..... 18
Atheroma pulmonary artery, **95**, 82, 83, 94..... 3
Atheroma of splenic artery, **89**, 60 1

ANEURYSM—

Sinus of Valsalva, **93**, 17..... 1
Arch of aorta, **83**, 725; **85**, 816; **86**, 86; **87**, 42; **90**, 4, 11, 25; **92**, 26; **94**, 32; **95**, 79..... 10
Thoracic aorta, **84**, 795..... 1
Abdominal aorta, **83**, 765; **86**, 15; **88**, 23; **92**, 54 (dissecting)..... 4
Innominate, **86**, 83..... 1
Subclavian, **92**, 54 1
Iliac, **84**, 765 (dissecting)..... 1
Mesenteric, **92**, 54, (dissecting multiple) 1
Splenic, **94**, 27..... 1
Renal. **95**, 24 1
Cerebral, **90**, 10..... 1
" (miliary,) **83**, 722; **84**, 787; **89**, 23..... 3
Cerebellar, **90**, 50..... 1
Pulmonary, **83**, 710; **90**, 48..... 2
Multiple, **92**, 54 1
Traumatic, **90**, 11..... 1

PERICARDIUM—

Hæmorrhage, **83**, 725; **87**, 87; **94**, 41; **95**, 57..... 4
Pericarditis (acute fibrinous), **84**, 803; **85**, 816; **86**, 81; **87**, 20, 25, 29; **88**, 79; **90**, 16, 36; **93**, 57, 48, 51; **94**, 21..... 14
Pericarditis, acute sero-fibrinous, **83**, 772; **88**, 39; **89**, 21; **93**, 62; **94**, 7, 25, 41; **95**, 18..... 8
Pericarditis, acute purulent, **91**, 31; **94**, 6..... 2
Pericarditis, hæmorrhagic, **93**, 33*a* 1
—tuberculous, **85**, 859; **86**, 55; **92**, 37 (hæmorrhagic), **95**, 96 ... 4
Pericarditis, chronic adhesive, **83**, 774; **85**, 865, 874; **86**, 21; **87**, 23, 37, 39, 84; **89**, 28, 60, 70; **90**, 28, 60; **92**, 52; **93**, 21, 33*a*, 37; **95**, 43, 66..... 19
Pericarditis with calcification, **95**, 37..... 1
Secondary cancer, **93**, 48, 51 2
Pericarditis sarcoma **85**, 840*a*, (ossifying); **86**, 21 (myeloid)..... 2

HEART—

Persistence of foramen ovale, **83**, 743; **89**, 49; **90**, 29; **92**, 21, 28; **95**, 18, 21*a* 7

MYOCARDIUM—

Cloudy swelling, acute parenchymatous myocarditis, **83**, 753; **86**, 8, 30, 57; **87**, 13, 41, 85, 90; **88**, 18, 32, 68, 72, 83; **89**, 29, 32, 35, 64; **90**, 55; **93**, 52; **94**, 15... 20
Fat infiltration, **87**, 49, 87; **88**, 58; **89**, 59; **94**, 47 5
Sub-endocardial lipoma, **94**, 86 .. 1
Fatty degeneration, **83**, 704, 732, 748; **85**, 832, 863; **86**, 2, 5, 73; **87**, 9, 25, 67; **88**, 58, 68, 84; **89**, 5, 6, 8, 29, 35, 37, 38, 50; **90**, 20, 25, 35, 68; **92**, 30; **93**, 31, 34, 41, 66; **94**, 10, 16, 43; **95**, 3, 43, 48, 49, 66..... 39

Myocardium.

Brown atrophy, **83**, 720, 730, 745; **85**, 844*a*; **87**, 12, 30, 34, 35, 74; **88**, 28, 40, 78, 79; **89**, 65, 66; **90**, 2, 6, 23, 30, 31, 53; **93**, 17, 42; **94**, 5, 18, 31; **95**, 14, 20, 21, 59, 85, 86, 87, 92, 94 35

Dilatation, **83**, 755, 761, 771, 776; **84**, 801; **86**, 5; **87**, 42, 84; **88**, 19, 23; **89**, 29, 37, 50; **90**, 35; **92**, 30; **94**, 60 16

Acute dilatation (right), **95**, 36 .. 1

Dilatation of left auricle, **86**, 18; **92**, 31 2

Hypertrophy and dilatation, **83**, 755, 761, 771, 776; **84**, 787, 797, 802, 810; **85**, 816, 821; **86**, 1, 7, 11, 23, 24, 49, 63, 73; **87**, 42, 84; **88**, 57, 68; **89**, 4, 19, 23, 28, 35, 43, 70, 72, 75; **90**, 1, 3, 14, 20, 21, 25, 28, 43, 60, 64, 65, 68; **95**, 2, 11, 13, 18, 20, 25, 39, 48, 59, 61, 75, 83, 86, 89 57

Left hypertrophy, **83**, 722, 767; **84**, 801; **85**, 872; **86**, 21, 47; **87**, 9, 40, 63; **88**, 71; **89**, 10, 74; **90**, 10, 66, 67; **91**, 30, 32, 37; **92**, 20, 40, 44, 52, 54; **95**, 5, 6, 15, 16, 76, 84 27

Right hypertrophy, **87**, 34 1

Myomalacia, **86**, 15; **87**, 87; **89**, 59; **92**, 39 4

Rupture, **86**, 15; **87**, 87; **89**, 59 .. 3

Acute aneurysm, left ventricle, **86**, 15 1

Aneurysm of pars membranacia, **90**, 1 1

Miliary abscesses, **88**, 21 1

Infarct, **93**, 15 1

Chronic interstitial myocarditis, **83**, 722, 745, 776; **91**, 42; **92**, 22, 35, 54; **93**, 30, 50, 65; **94**, 14; **95**, 11, 16, 20, 76, 81 16

Gumma of myocardium, **94**, 71 ... 1

Tubercle of myocardium, **90**, 41 .. 1

Trauma of heart, **95**, 40 1

Puncture wound of coronary vein, **94**, 41 1

VALVES

Endocarditis -a, aortic; m, mitral; t, tricuspid; p, pulmonary.

Acute verrucose, **3**, 768, 769; **4**, 798, a; **6**, 74, m; 38, 42, a; 43, a; **7**, 10, m; **89**, 70, a; **90**, 36, a; **91**, 46, m; **95**, 15, m 13

Recurrent (chronic and acute), **84**, 801; **85**, 852, a; **86**, 1, 21, 36, m; **87**, 29, 41, m; 74, m and t; **88**, 18, m; 57, m; **89**, 28, a; 70, m; **93**, 47, m; **94**, 21, m and t; **95**, 28, m and a; 71, m and a; 13, a; 25, 39; 17, m; 31, m 21

Chronic sclerotic (marginal thickening), **83**, 743, m; 722, 761, 771, a; 776, m; 778, m and a; **85**, 816, m and a; 861, m and a; **85**, 5, m and a; 7, m and a; 11, m, a, and t; 24, a; 36, t; 42, m; 43, m; 68; **87**, 1, m; 35, m; 36, m; 40, m; 44, m; 67, m; 75, 80, m; 44, m and a; 91, m; **88**, 26, a and t; 29, m and a; 88, a; **89**, 4, 14, m; 15, a and p; 28, m; 23, m and t; 72, m; **90**, 1, a and m; 3, m; 18, m; 25, a; 28, a; 30; 40, m; **91**, 38, m; **92**, 31, m; 41, m; **93**, 16, m and a; 30, 21; **94**, 25, m; 32, m and a; **95**, 1, m; 13, m; 17, m; 18, m and a; 25, m; 43, m; 44, m; 62, m; 65, m; 81, m; 89, m and a; 99, m and t; 74, m and t; 85, m and t 80, 92; m, 3 69

Atheroma of valves (basilar thickening), **83**, 703, m and a; 728, m and a; **84**, 787; **85**, 833, a; 844, a; **86**, 9, a; 44, a; 46, a and m; **88**, 28, 79, p and a; **89**, 35, a; 50, 74, m; **91**, 42, a and m; **92**, 52, a; 55, a; 60; **94**, 16, 43; **95**, 63, m and a; 75, 79, 91, 93, 46, 59 27

Ulcerative endocarditis, **83**, 708, 724, 771; **84**, 786; **85**, 818; **86**, 23, 31; **88**, 21; **90**, 15, m and a; 36, 64, a; **90**, 15, m and a; 36, 64 a; **91**, 51; **95**, 71 15

Valves—
Incompetence of valves, **83**, 776; **84**, 810; **85**, 816, m; **86**, 1, a; 5, a and m; 42, t; **87**, 84, a; **88**, 57, m; **89**, 15, a; 28, a; **90**, 25, a; **93**, 21, a; **95**, 89 14
Stenosis, **83**, 743; **87**, 29, 40, m; 41, m; 44, m and a; **92**, 31, m; 40, m; **94**, 25, m; **95**, 17, 25, 43, 44, 80 m 13
Perforation, **83**, 708; **95**, 71 2

Valves—
Endocarditis, gummatous syphilitic, **95**, 71 1
Polypoid vegetation (musical murmur), **86**, 21; **95**, 17 2
Thrombi (see thrombi of heart).
Ecchymoses of endocardium, **88**, 29; **93**, 40; **94**, 4; **95**, 65 4
Ecchymoses of papillary muscles, **93**, 78 1

LYMPHATIC SYSTEM.

LYMPH GLANDS—
Mesenteric acute hyperplasia (typhoid), **93**, 749, 750, 758, 769; **86**, 87; **87**, 16, 68, 72, 73; **89**, 39, 42, 49; **95**, 71, 93 15
—leuchæmia, **83**, 404 1
—ch. hyperplasia, **83**, 748; **86**, 1. 2
—calcification, **93**, 56 1
—abscess, **95**, 41 1
—tuberculosis, **83**, 710; **86**, 38; **87**, 84; **92**, 46; **93**, 19, 54; **95**, 22, 29, 72, 93 11
—chyle extravasations, **83**, 734 1
—secondary cancer, **85**, 834; **91**, 43 2
Bronchial.
—suppuration, **94**, 13 1
—hæmorrhagic (typhoid), **92**, 4 1
—enlarged, **84**, 783; **94**, 62 2
—lympho-sarcoma, **94**, 29 1
—caseous and tuberculous, **84**, 783; **85**, 865; **86**, 12; **87**, 35, 69; **88**, 60, 88; **89**, 37, 61, 65, 73; **90**, 16, 17, 25, 29, 41; **91**, 39; **92**, 56; **93**, 36, 48; **94**, 3, 9; **95**, 28, 29, 72, 77 24
—miliary tubercle, **94**, 783 1

Lymph Glands.
Mediastinal sec. cancer, **89**, 56; **92**, 33 2
Cervical lymphadinitis, **85**, 707; **93**, 30*a*, 52 3
—abscess, **95**, 3 1
—tuberculous, **87**, 73 1
—gout (tophi), **88**, 47 1
Retropharyngeal, tuberculous abscess, **90**, 24 1
Axillary tuberculous, **88**, 28 1
Portal enlarged, **83**, 707 1
sec. cancer, **90**, 23; **92**, 33 3
—sarcoma, **85**, 854 1
Epigastric caseous, **90**, 41 1
—sec. cancer, **88**, 67 1
Retro-peritoneal leuchæmia, **83**, 704 1
—acute swelling, **87**, 10 1
—sec. cancer, **83**, 745; **85**, 834, 869; **83**, 8; **89**, 11; **92**, 33; **93**, 11, 42; **95**, 51 9
—sec. sarcoma, **85**, 840*a* 1
—pelvic sec. cancer, **90**, 20 1
—sarcoma, **99**, 60 1
—abscess, **85**, 856; **95**, 46 2

Lymph Glands.

inguinal sec. epithelioma, **83**, 702; **88**, 69; **93**, 11; **95**, 51, 74 . 5
—sec. cancer, **86**, 56 1

THORACIC DUCT—

Tuberculosis, **87**, 12; **89**, 28..... 2

SPLEEN—

Supernumerary, **83**, 747; **84**, 783; **87**, 94, 95; **89**, 53; **93**, 22; **95**, 19, 84 8
Infarcts, **83**, 771, 779; **84**, 810; **85**, 833, 852, 856, 859; **86**, 11, 31; **87**, 29, 40, 41, 91; **88**, 16, 21, 29; **89**, 7, 35, 53, 66; **90**, 1, 15, 18, 29, 42, 43; **92**, 51; **93**, 47; **94**, 7, 11, 21. 31
Acute enlargement (acute hyperplasia, **83**, 708, 749, 758, 769, 779; **85**, 851*a*, 858, 887; **86**, 18, 30, 31, 55, 57, 82, 85; **87**, 2, 13, 15, 19, 45, 58, 62, 68, 71, 72, 73, 74, 86, 88; **88**, 11; **89**, 2, 7, 14, 26, 32, 33, 38, 39, 42, 49, 52, 53; **90**, 36, 47, 55, 64, 69; **91**, 35; **92**, 21; **93**, 39*a*, 38, 52, 54; **94**, 36, 38, 39, 45; **95**, 5, 19, 41, 53, 69, 71, 93 64
Enlargement, **83**, 748, 705, 766, 754, 769, 771; **84**, 781, 790, 810, 812; **85**, 885; **89**, 61; **90**, 11, 39; **91**, 29; **92**, 51; **94**, 19, 30, 37, (extreme); **95**, 2, 12, 16, 45, 66, 68, 78*a* 26
Chronic enlargement (chronic hyperplasia), **83**, 747, 761, 776; **85**, 821, 863, 864; **87**, 25; **88**, 5, 42, 51; **89**, 28; **90**, 16, 25; **93**, 45, 47; **95**, 13, 52, 56, 79, 91..... 17
Fibroid induration, **86**, 1, 5; **94**, 2 3
Cyanotic induration, **87**, 44, 87, **90**, 1, 2, 8, 60..... 5
Leuchæmia, **83**, 704; **94**, 1..... 2
Miliary tuberculosis, **83**, 709, 754; **84**, 782, 783; **85**, 870, 879; **86**, 12; **87**, 5; **88**, 1, 27; **90**, 29, 40, 41; **92**, 37; **93**, 19, 36; **95**, 48, 49, 87, 92..... 21
Tuberc. cheesy nodules, **95**, 37.... 1

Spleen.

Chalky nodules, **95**, 36, 96..... 2
Gumma, **92**, 32..... 1
Amyloid (see degenerations), p. 87
Abscess, **87**, 57; **90**, 13, 23..... 3
Cysts, **90**, 57..... 1
Hæmatoma (beneath capsule), **90**, 49 1
Perisplenitis, chronic adhesive, **83**, 730, 748; **87**, 45; **93**, 55; **94**, 7, 26. 6
Thickening of capsule, **83**, 722, 748; **87**, 74; **89**, 60; **90**, 5, 28... 6
Laceration (rupture), **83**, 757; **85**, 871; **95**, 40, 84 4
Hæmorrhage, **88**, 26..... 1
Ecchymosis, **95**, 85 1

ADRENALS—

Accessory, **94**, 9 1
Aberrant, **87**, 73 1
Enlarged, **89**, 63; **90**, 56; **95**, 18. 3
Malignant adenoma, **90**, 51..... 1
Benign adenoma, **95**, 81 1
Tuberculosis, **85**, 865, 874; **86**, 28, 38, 41, 42; **87**, 5 7
Atrophy, **85**, 864 1
Gray degeneration, **93**, 22 1
Necrosis, **93**, 42..... 1
Amyloid, **95**, 94..... 1

THYROID GLAND—

Inclusion, **94**, 11..... 1
Exophthalmic goitre, **88**, 16 1
Accessory thyroid, **95**, 96 1
Cystic bronchocele, **88**, 16 1
Abscess, **92**, 25 1

THYMUS—

Ecchymosis, **95**, 67..... 1
Persistence of enlarged, **95**, 88 ... 1

BONE MARROW—

Leuchæmia lymphoid (pyoid) hyperplasia, **83**, 748 1
Hyperplasia, **85**, 863; **95**, 20, 66.. 3
Cancerous degeneration, **87**, 8.... 1

RESPIRATORY SYSTEM.

PLEURA—

Ecchymosis, **88**, 63; **89**, 14; **95**, 32, 67, 72, 85, 92 7

Pleurisy (acute) **83**, 738, 753; **84**, 803, 813; **85**, 816, 827, 876; **86**, 5, 6, 25, 44, 57, 46, 58, 66, 81; **87**, 2, 6, 13, 19; **88**, 8, 10, 11, 32, 36, 49; **90**, 2, 20, 30, 32, 36, 49; **91**, 31, 37, 40, 41, 42; **92**, 45, 51; **93**, 27, 29, 38, 48, 57; **94**, 29, 36; **95**, 16, 18, 39. 43

—acute serofibrinous, **83**, 772; **84**, 789; **85**, 815; **86**, 18, 46, 47; **87**, 29, 38, 79; **88**, 51; **89**, 47, 70; **90**, 14, 28, 61 15

—empyæma, **87**, 29, 55, 79; **89**, 27, 38; **92**, 59; **95**, 26, 78*a* 8

—necrosing, **89**, 54; **95**, 26 2

Pneumothorax (see pleura p)

—chronic adhesive, **83**, 703, 780; **84**, 783; **85**, 826, 837, 864; **86**, 68, 70; **87**, 11, 30, 34, 35, 36, 37, 39, 45, 61, 79, 82; **88**, 11, 17, 27; **89**, 27, 34, 69; **90**, 12, 15, 20, 25, 29, 53; **92**, 27, 35, 58, 60; **93**, 33, 37, 55, 57, 60; **94**, 9, 32, 40; **95**, 16, 27, 38 (ordinary adhesions not included) 46

Pleurisy (acute hæmorrhagic), **94**, 15 1

Pleurisy tuberculous (ac. hemorrhagic), **83**, 709, 754, **87**, 20; **93**, 40 4

— in miliary tuberculosis, **84**, 782; **95**, 87, 80 3

—tuberculous, with effusion, **83**, 741; **84**, 798; **85**, 837, 859, 874; **86**, 12, 14, 24, 35, 41, 75; **89**, 1, 60; **90**, 62, 29, 41, 51; **92**, 34, 50; **95**, 35, 87, 96 21

Perforative pneumothorax, **83**, 706; **84**, 808; **85**, 826; **89**, 54; **92**, 34 5

Trauma, **87**, 48; **86**, 25 2

Cancer of, **86**, 66; **91**, 40*a*; **93**, 48 3

Sarcoma, (ossifying) **85**, 840*a*; (lympho), **86**, 48; **89**, 41; **93**, 58. 4

Bronchocele (?) cyst, **83**, 702 1

Hæmothorax, **85**, 826; **87**, 21 2

Pleura.

Fibroid pseudo tubercles, **83**, 745. 1

Diaphragmatic hernia, **85**, 851 ... 1

—calcified plate in, **83**, 703, **85**, 864; **92**, 27 3

—cartilaginous looking plate, **83**, 703 1

LUNGS.

Œdema, **83**, 708, 723, 727, 748, 749, 756, 764, 767, 778; **84**, 787, 796, 797; **85**, 878; **86**, 46, 65; **87**, 38, 40, 51, 52, 63, 77; **88**, 23, 57, 58, 68; **89**, 19, 28, 29, 34, 38; **90**, 20, 35, 54; **91**, 29, 32; **92**, 42, 58; **93**, 11, 16, 35, 63; **94**, 11, 18, 36, 37; **95**, 1, 20, 37, 61, 66, 69, 82 52

Congestion and œdema, **93**, 21, 28, 33*a*, 55, 56, 61; **94**, 2, 12; **95**, 2, 12, 18, 25, 41, 65, 73, 81 16

Hæmorrhagic infarction, **83**, 762, 778; **85**, 852; **86**, 23, 54, 57, **87**, 41, 42; **88**, 29; **89**, 35, 58, 69, 72; **90**, 11, 43; **94**, 5, 10, 38 18

Pulmonary embolism, **85**, 866; **86**, 30; **89**, 69, 70; **90**, 14; **92**, 42; **93**, 54; **95**, 31 8

Fat embolism, **95**, 60 1

Brown induration, **83**, 776; **86**, 1, 5; **87**, 84; **89**, 72, 74; **90**, 18, 60; **92**, 31; **93**, 47; **94**, 25, 31, 70, 71 14

Hæmoptysis, **83**, 710; **90**, 48 2

Pulmonary apoplexy, **83**, 753; **85**, 871; **86**, 54; **87**, 6, 36, 40, 68, 89; **89**, 58; **94**, 33, 38, 62, 68, 83, 84, 88 16

Inflation, **83**, 715; **85**, 835; **88**, 30; **89**, 57; **92**, 41, 57; **95**, 21, 88, 99 9

Collapse (atelectasis), **83**, 715, 740, 764; **84**, 798; **85**, 839, 826 (induration); **86**, 5, 46, **87**, 31*a*, 92; **88**, 12, 24, 31, 55; **89**, 14, 27, 39, 49; **90**, 16; **93**, 12; **94**, 11 21

Compression atelectasis, **87**, 29; **94**, 32 2

Lungs.

Emphysema, **83**, 710, 722, 726, 729, 732; **84**, 787; **86**, 9, 11, 17; **87**, 21, 43, 49, 51, 57, 67, 74, 82; **88**, 19, 27, 48; **89**, 62, 74; **90**, 2, 5, 28, 35, 43, 65; **91**, 42; **92**, 44, 58; **93**, 28, 33, 34, 65; **94**, 6, 8, 14, 16; **95**, 4, 17, 20, 25, 39, 66, 70, 76, 80. 49

Emphysema (interstitial), **87**, 94.. 1

Pneumonia (acute lobar), **83**, 766, 771, 772; **84**, 790, 803; **85**, 815, 818 819, 831, 838, 858,; **86**, 23, 25, 26, 44, 47, 81; **87**, 90; **88**, 8, 10, 22, 32, 37, 42, 43, 60, 66, 83, 84; **89**, 10, 52, 58, 65; **90**, 1, 2, 13, 21, 30, 36, 43, 49; **91**, 30, 37; **92**, 27; **93**, 24, 27, 29, 30, 38, 55, 56; **94**, 2, 12; **95**, 16, 17, 18, 24, 39, 45, 49, 79. 60

acute bronchio, **83**, 707, 729, 749, 750; **84**, 783, 799, 796; **85**, 828, 830, 834, 858, 865, 872, 889; **86**, 17, 62, 68, 82, 83; **87**, 9, 23, 38, 46, 48, 71, 72, 73, 92, 95; **88**, 9, 15, 17, 24, 25, 29, 30, 31, 43, 55, 63, 64, 86; **89**, 9, 36, 38, 52, 57, 61, 67, 70; **90**, 7, 8, 19, 20, 23, 27, 54, 61, 63; **91**, 34, 38, 41; **92**, 41, 52, 56, 57; **93**, 19, 30, 35, 48, 50, 61; **94**, 3, 6, 8, 34, 42; **95**, 15, 20, 28, 37, 39, 63, 70, 86..... 84

Pneumonia hypostatic, **83**, 776; **85**, 853; **86**, 14; **88**, 25, 29..... 5

Chronic interstitial, **83**, 709, 780; **86**, 81; **88**, 24; **89**, 65; **90**, 25, 40, 64; **92**, 55; **94**, 9; **95**, 16... 16

Chalicosis, **89**, 65; **90**, 64..... 2

Aspiration, **89**, 9; **91**, 43; **95**, 41. 3

—sesquioxide iron, **95**, 85..... 1

—embolic (and miliary abscess), **86**, 9, 57; **87**, 86; **88**, 55, 58; **89**, 53; **92**, 59; **93**, 50, 54; **94**, 10; **95**, 52..... 11

—gangrenous (dissecting), **89**, 70; **90**, 14, 52; **95**, 26, 78*a*, 80..... 6

Gangrene, **86**, 1; **88**, 66; **92**, 60; **93**, 24..... 4

Lungs.

Chronic phthisis with cavities, **83**, 701, 706, 709, 710, 726, 730, 731, 734, 738, 741, 747, 754, 766, 768; **84**, 804, 808; **85**, 828, 835, 838, 859, 870, 874, 879, 880, 882; **86**, 4, 14, 28, 34, 35, 38, 39, 41, 42, 50, 52, 56, 75, 79, 84; **87**, 11, 12, 16, 30, 31, 34, 37, 38, 39, 43, 47, 51, 69, 77, 82, 93; **88**, 1, 27, 35, 47, 49, 78; **89**, 17, 34, 41, 66; **90**, 6, 9, 12, 29, 40, 48, 58, 62; **92**, 34, 46, 48, 50; **93**, 20, 23, 49, 60; **94**, 3, 6, 9, 16, 20, 21, 23, 28, 40; **95**, 21, 27, 44, 54, 64, 73, 77, 80, 89, 98 101

Miliary tuberculosis, **83**, 733, 744; **84**, 782; **85**, 825, 837, 879; **86**, 12, 36, 70, 73; **87**, 3, 5, 30, 55, 79, 81, 82; **90**, 41, 51; **92**, 32, 37, 43; **93**, 19, 36, 56; **94**, 5, 34; **95**, 3, 29, 48, 92 30

Local apical tuberculosis, **83**, 714, 732, 733, 767; **84**, 796; **85**, 837, 865, 866, 885, 886; **86**, 24, 46; **87**, 61; **88**, 60, 68; **89**, 1, 11, 15, 16, 32, 37, 50, 60, 74; **90**, 51; **91**, 29, **93**, 28, 33, 46, 56; **94**, 5, 13, 16, 21*a*, 25; **95**, 12, 46, 20, 35, 45, 53, 78*a*, 79, 99 44

—(not apical), **85** 859; **87**, 7; **88**, 28, 97; **90**, 31, 41..... 6

LUNGS—

Secondary cancer, **83**, 737, 759, 762; **86**, 27, 56, 66; **93**, 48..... 7

Gumma, **88**, 65; **92**, 32 2

Secondary sarcoma, **85**, 840*a* 1

Primary lympho sarcoma, **86**, 48.. 1

Secondary " " **86**, 48.. 1

Secondary epitheloma, **86**, 6; **90**, 52; **95**, 74..... 3

Tuberculous fistula, **95**, 77 1

Bronchiectatic cavities, **94**, 32 1

Imperfect lobulation, **85**, 872; **93**, 38, 61 3

Laceration, **88**, 25; **95**, 38, 54, 57. 4

Anthracosis, **83**, 745; **94**, 42; **95**, 63 3

BRONCHI—

Acute Bronchitis, **83**, 702, 722; **87**, 6, 17, 62, 91; **88**, 8, 32, 60; **89**, 2, 9, 50, 70; **90**, 35; **91**, 30; **93**, 51, 52, 56; **94**, 2, 5, 8, 13; **95**, 5, 72, 77, 93 25
—capillary, **84**, 783; **85**, 839; **88**, 70; **95** 86 4
Bronchitis chronic, **83**, 729, 745, 761, 778; **84**, 799; **87**, 9, 35, 49, 57, 70, 74; **88**, 23, 58, 69; **89**, 50; **90**, 35, 64; **92**, 58; **93**, 28, 33, 34, 37, 65; **94**, 14; **95**, 17, 25, 70, 80, 86, 90 30
—bronchiectasis, **90**, 64; **94**, 32, 42; **95**, 25, 80 5
—chronic putrid, **88**, 9; **89**, 67; **94**, 6, 42 4
—dipththeritic, **83**, 763; **89**, 70; **95**, 65 3
Food aspiration, **95**, 88 1
Mucus " **95**, 67 1
Antidote " **95**, 33 1
Secondary epithelioma, **86**, 67 1

TRACHEA—

Diphtheria, **83**, 763; **84**, 799; **86**, 45, 82; **87**, 46, 92, 94, 95; **88**, 4, 24, 30, 31; **89**, 70; **91**, 41; **92**, 41, 56, 57 17
Croup, **89**, 58, (anatomical) 1
Granulomata, **95**, 837 1
Ulceration, **87**, 16 1
Secondary epithelioma, **87**, 35 1
Compression (aneurism), **90**, 4; **94**, 29, 32 3

LARYNX—

Œdema of glottis, **85**, 837; **87**, 17, 77; **89**, 8; **95**, 61 5
Obstruction by mucus, **95**, 67 1
Asphyxia by food, **86**, 13; **88**, 70; **90**, 24 3

Nose Pharynx and Tonsils.

Laryngitis catarrhal, **83**, 705, 715; **85**, 832; **87**, 17; **90**, 27 5
—phlegmonous, **93**, 31 1
—syphilitic ulceration, **84**, 796; **93**, 50; **95**, 5 3
—tuberculous, **85**, 828, 837; **86**, 39, 42, 52; **87**, 16, 34, 38, 47, 51, 93; **88**, 5, 27; **89**, 17, 41; **90**, 29, 40; **93**, 54; **94**, 21; **95**, 80 20
—diphtheritic, **83**, 707, 715; **84**, 799; **86**, 45, 82; **87**, 46, 92, 94, 95; **88**, 15, 24, 29, 30, 31, 55; **89**, 57, 70; **91**, 41; **92**, 41, 56, 57; **94**, 3 22
—croupous, **88**, 4 23

NOSE PHARYNX AND TONSILS—

Rhinitis ac., **93**, 56 1
—ch. hypertrophic, **90**, 26, 61 2
—ch. atrophic, **88**, 6 1
—diphtheritic, **83**, 711, **87**, 31a, 78; **88**, 29 4
Pharynx diphtheria, **83**, 707, 711, 733 5
Pharyngitis, **93**, 30a, 35; **95**, 83 3
Ulceration tuberculous, **87**, 37 1
Ulceration syphilitic, **89**, 47 1
Diphtheritic, **83**, 707, 711, 733; **84**, 799; **86**, 45, 82; **87**, 19, 31a, 46, 66, 78, 85, 92, 94; **88**, 15, 24, 29, 30, 31, 55, 86; **89**, 57, 70; **91**, 41; **92**, 56, 57 26
Tonsillitis diphtheritic, **83**, 707, 711, 733; **84**, 783; **92**, 57; **93**, 61. 6
—suppurative, **84**, 13 1
—follicular, **87**, 2 1
—concretion, **90**, 9 1
Uvula bifid, **84**, 783 1
Parotitis purulent, **86**, 57 1

DIGESTIVE SYSTEM.

TONGUE—

Tuberculous ulcer, **88**, 52..... 1
Hemiatrophy, **89**, 74 1
Epithelioma, **90**, 52..... 1
Purpuric ecchymosis typhoid, **94**, 4 1
Gangrenous stomatitis, **95**, 19 1

ŒSOPHAGUS—

Ulceration, **85**, 815..... 1
—tuberculosis, **93**, 60..... 1
Epithelioma, **85**, 815; **86**, 6, 67; **87**, 35; **90**, 24; **91**, 43; **93**, 51.. 7
Rupture of aneurysm, **92**, 26..... 1

STOMACH—

Ecchymosis, **88**, 63; **89**, 7, 47, 69, 73; **93**, 40; **95**, 86..... 7
Hæmorrhage (hæmatemesis), **89**, 6; (ulcer); **90**, 11 (aneurysm) 2
Thrombosis, **89**, 69..... 1
Œdema, **95**, 86..... 1
Gastritis (acute catarrhal), **86**, 60, 61; **88**, 26; **93**, 30, 61; **95**, 71, 85, 86..... 8
—chronic catarrhal (atrophic), **83**, 739; 761, 766; **84**, 782, 802; **85**, 864; **86**, 62; **87**, 70; **88**, 38; **89**, 7, 23, 25, 35, 43; **92**, 58; **93**, 22; **95**, 2, 5, 35..... 21
—hypertrophic cystic, **87**, 63; **93**, 37; **95**, 66. 3
—polypoid, **88**, 28; **95**, 96..... 2
Cirrhosis of stomach, **88**, 20..... 1
Hæmorrhagic erosion, **84**, 783; **89**, 64..... 2
Round ulcer, **87**, 47, 60; **88**, 20; **89**, 6; **90**, 22, 54; **92**, 35; **93** 51; **95**, 73. 9
—cicatriced, **89**, 20; **93**, 55..... 2
Perforation of ulcer, **88**, 20; **93**, 51. 2
Annular ulcer, **88**, 28 (tuberculous) 1
Dilatation, **85**, 823; **86**, 16, 76, 77; **89**, 23, 37; **93**, 22, 59..... 8
Stenosis of pylorus, **86**, 16. 1
Slaty pigmentation, **95**, 2 1

Stomach.

Amyloid, **95**, 94 1
Stomach cancer, **83**, 745; **85**, 823; **86**, 16, 66, 72, 76; **87**, 8; **88**, 13; **89**, 15, 48, 56; **90**, 23, 53; **92**, 35; **93**, 51; **95**, 81 16
—sarcoma (sec.) **95**, 51..... 1
Villous papilloma, **95**, 96 1

DUODENUM—

Round ulcer, **90**, 32; **95**, 74 2
Tuberc. ulcer, **86**, 36 1
Carcinoma (sec.) **86**, 27..... 1
Epithelioma (sec.), **95**, 74..... 1
Polypoid adenoma, **86**, 38..... 1

JEJUNUM AND ILEUM—

Hyperæmia, **88**, 19; **93**, 16, 25.... 3
Ecchymosis, **88**, 63 1
Hæmorrhagic infarction, **83**, 708 . 1
Slaty pigmentation, **86**, 71; **87**, 92; **88**, 11; **89**, 49, 71; **95**, 41, 91 7
Enteritis (acute) catarrhal, **86**, 38, 60, 61; **87**, 2, 23, 25, 75, 76; **88**, 26, 83; **89**, 1, 35, 37, 53; **90**, 54; **93**, 33, 41, 44, 61; **94**, 42; **95**, 50, 62 21
—ulc. follicular, **87**, 60, 76; **95**, 91. 3
—ulcerative catarrhal, **87**, 63, 90 . 2
Enlargement of follicles, **83**, 865; **87**, 4, 80; **89**, 29; **95**, 55; **93**, 59 7
Leuchæmic enlarg. follicles, **83**, 704 1
Calcification of follicles, **87**, 84 ... 1
Rupture, **89**, 13 1
Contusion of serosa, **95**, 38 1
Amyloid, **83**, 60; **95**, 94..... 2
Distension, **86**, 53, 60 2
Fistula, **91**, 20..... 1
Œdema, **95**, 85..... 1

Jejunum and Ileum.

Tuberculous ulceration, **83**, 709, 730, 731, 734, 738, 741; **85**, 870, 882; **86**, 12, 26, 34, 38, 39, 41, 42, 52, 55, 73, 75, 79; **87**, 3, 11, 16, 34, 39, 47, 51, 77, 82, 84, 93; **88**, 27, 47, 49, 78; **89**, 17, 41, 68; **90**, 29, 40; **92**, 34, 46, 48; **93**, 20, 56; **94**, 20, 23, 40, 45; **95**, 44, 64, 80..... 50

Typhoid ulceration, **83**, 749, 750, 758, 763, 769, 779; **84**, 812; **85**, 851, 853, 856, 862, 878, 887; **86**, 2, 55, 82; **87**, 53, 57, 58, 62, 68, 71, 72; 76; **88**, 67; **89**, 26, 32, 33, 39, 42, 49, 64; **90**, 47; **92**, 28, 51; **93**, 39; **94**, 4, 38, 39; **95**, 53, 69, 72, 73, 93..... 43

Typhoid perforation, **87**, 53, 71; **89**, 26; **92**, 28; **94**, 4; **95**, 69.. 6

INTESTINE—

Meckel's diverticulum, **85**, 872, 885; **86**; 63, ; **87**, 21..... 4

Strangulation (gangrene), **85**, 860; **86**, 22, 62; **88**, 65; **89**, 18; **92**, 55; **95**, 11, 41, 68..... 9

Gangrene from embolism sup. mesenteric artery, **95**, 11..... 1

Melæna neonatorum, **86**, 10, 59.. 2

Ascarides, **87**, 33, 70; **88**, 26, 30. 4

COLON.

Œdema, **95**, 85..... 1

Melæna, **85**, 868; **89**, 6, 47, 49.... 4

Colitis acute catarrhal, **83**, 704; **84**, 811; **85**, 864, 874; **89**, 31, 37, 63; **93**, 30, 37, 38; **95**, 15..... 10

Chr. dysentery, **83**, 767; **85**, 824; **89**, 22, 26..... 4

Amœbic dysentery, **94**, 7..... 1

Diphtheritic colitis, **95**, 51, 84..... 2

Syphilitic ulceration, **88**, 65 1

Cicatriced ulcers, **85**, 864; **87**, 75. 2

Follicular ulcers, **86**, 26; **95**, 69.. 2

Tuberculous ulceration, **83**, 709; 730, 734, 741; **84**, 783; **86**, 41, 55, 73; **87**, 79: **92**, 48; **93**, 36, 80; **94**, 40, 45..... 14

Adeno carcinoma (primary), **89**, 9, 11, 30; **95**, 97..... 4

Colon—

—secondary, **89**, 15; **90**, 31 2

Bullet wound, **85**, 851*b*..... 1

Perforation, **86**, 41 1

Atrophy of walls, **93**, 34 1

Diverticula, **90**, 30; **95**, 92; **94**, 21*a*..... 3

Obstruction, **85**, 860; **88**, 30; **94**, 21*a*, 31; **95**, 41, 68 6

RECTUM.

Dextro position, **86**, 15, 47; **90**, 54 3

Hæmorrhoids, **86**, 36; **87**, 38, 74; **88**, 68; **89**, 60; **95**, 12..... 6

Œdema, **95**, 49..... 1

Slaty pigmentation, **95**, 69, 91 2

Fistula in ano, **89**, 60; **86**, 36.... 2

Recto-vesical fistula, **84**, 781; **89**, 11; **93**, 41; **95**, 12, 31 5

Urethral, **87**, 5, 81 2

Tuber. ulceration, **84**, 781; **87**, 5, 16, 82; **88**, 49; **95**, 68..... 6

Ulceration syphilitic, **84**, 781; **90**, 54 2

—follicular, **95**, 68 1

Typhoid, **85**, 862; **90**, 54 2

Stricture, **84**, 781; **85**, 843, 846; **94**, 22, 31..... 5

Sloughing, **85**, 849 1

Adenoma, **88**, 63..... 1

Lipoma, **93**, 55 1

Cancer (primary), **85**, 834; **86**, colloid, 56; **89**, 69; **94**, 31..... 4

—(secondary), **83**, 719; **90**, 31.... 2

APPENDIX.

Ulcerative appendicitis, **83**, 780, 861; **84**, 809; **85**, 861; **86**, 20, **87**, 33, 50; **88**, 39, 72, 79; **89**, 24, **90**, 69; **92**, 36, 47: **93**, 39, 66; **94**, 33; **95**, 41, 73, 87. Removed, **95**, 42, 47..... 22

Follicular appendicitis, **95**, 91.... 1

Catarrhal " **94**, 1. 1

Obliterative appendicitis, **85**, 869; **86**, 60; **95**, 78..... 3

Appendix.

—appendicitis (dilatation), **87**, 11. 1
Abscess, **88**, 79 1
Typhoid ulcers, **89**, 49; **95**, 62.... 2
Tuberculous ulcers, **95**, 80 1
Concretions, **86**, 39; **87**, 50; **89**, 24, 58; **90**, 54; **95**, 3, 13 7
Dilatation, **87**, 11 1

LIVER—

Liebermeister's furrows, **83**, 701, 761; **87**, 49; **90**, 25, 67; **93**, 16, **95**, 18. 7
Elongation L. lobe, **83**, 708, 731, 739; **85**, 856, 876; **86**, 4; **87**, 5, 7, 14..... 9
Atrophy left lobe, **86**, 9 (obliteration, hepatic veins) 1
Lacing lobe, **85**, 829; **89**, 9, 10; **95**, 19 4
Ecchymosis, **83**, 727, 750; **89**, 49 . 3
Cloudy swelling, **83**, 750, 769; **84**, 781; **86**, 8, 18, 30, 31, 55, 57; **87**, 2, 13, 15, 36, 68, 90; **89**, 7, 14, 32, 33, 38, 39, 73; **90**, 36, 47, 55, 64, 69; **91**, 35, 38, 41; **92**, 21, 28, 51; **93**, 38, 39, 41, 54; **94**, 15; **95**, 15, 62, 65, 72, 75, 93 44
Fatty, **83**, 701, 703, 723, 729, 731; **84**, 812; **85**, 821, 837, 838; **86**, 50; **87**, 20, 36, 37, 73; **88**, 5, 27, 39, 47, 68, 78; **89**, 22, 27, 31, 39, 49, 52; **90**, 8, 30, 43; **92**, 27, 58, 61; **93**, 12, 26, 35, 44, 50, 52, 59, 62, 63, 66; **94**, 8, 11, 30, 43; **95**, 45, 48, 64, 85..... 50
Fatty degeneration central zone, **83**, 748; **95**, 66..... 2
Cyanotic atrophy, (nutmeg), **83**, 714, 717, 719; **84**, 797; **85**, 826, 852; **86**, 11; **87**, 34, 74, 84; **88**, 18, 19, 26, 57; **89**, 43, 50, 70, 72; **90**, 14, 18, 25, 28, 35; **93**, 21, 28, 45, 47; **94**, 27, 45; **95**, 1, 3, 21, 44, 46, 63, 70, 71, 79, 89, 96 40
Brown atrophy, **87**, 12, 16; **88**, 40; **89**, 1, 23, 37; **90**, 53; **93**, 22; **94**, 31; **95**, 9, 47, 59, 66, 80.. 14

Liver.

Cirrhotic, **83**, 743, 766, 778; **84**, 790, 802; **86**, 5, 62; **87**, 41, 44, 61; **88**, 8, 26; **89**, 35, 62, 66; **90**, 54; **91**, 37; **92**, 25; **93**, 35, 38, 40, 44, 55, 62; **94**, 1, 19, 37; **95**, 25, 27, 70, 71..... 31
Cirrhotic and Fatty, **83**, 745, 753; **84**, 785, 796, 804, 810; **85**, 855; **86**, 37; **89**, 5, 6; **91**, 29; **94**, 23; **95**, 39, 61..... 14
Biliary cirrhosis, **94**, 27..... 1
Hypertrophic cirrhosis, **95**, 91.... 1
Abscess, **84**, 809; **85**, 824; **88**, 39; **92**, 24, 36; **94**, 7..... 6
—multiple (pylephlebitis), **86**, 20; **94**, 10; **95**, 73..... 3
Amyloid (see degenerations), ...
Syphilitic hepatitis diffuse, **93**, 52 1
Perihepatitis chronic fibrous, **83**, 730, 741; **84**, 789; **86**, 6; **89**, 37; **93**, 14, 33, 38, 58; **94**, 32; **95**, 12, 25, 36, 37..... 15
—tuberculous, **83**, 730; **87**, 55.... 2
Miliary tuberculosis, **83**, 754; **84**, 782, 783; **95**, 825, 870, 874, 879; **86**, 12, 73; **87**, 3, 5, 69, 79, 81; **88**, 1, 5, 27; **90**, 29, 31, 40, 41; **92**, 37, 43; **93**, 19, 23, 36, 40; **95**, 44, 49, 54..... 29
Gumma, **88**, 22, 51, 65; **91**, 42; **92**, 32; **95**, 71..... 6
Angioma, **87**, 45, 68, 82, 89; **89**, 15; **90**, 10, 25; **94**, 39..... 8
Leuchæmia, **83**, 704; **94**, 1. 2
Carcinoma (primary), **83**, 759; **92**, 33 2
—(secondary), **84**, 788; **86**, 27, 60; **87**, 1, 8; **88**, 13, 69; **89**, 11, 15, 30, 48, 67; **91**, 43; **92**, 33, 35; **93**, 42, 58 17
Epithelioma, (secondary) **95**, 74... 1
Sarcoma (secondary), **88**, 43; **95**, 51 2
Cysts, **88**, 21..... 1
Calcareous (nodules), **94**, 10, 39; **95**, 36 3

Liver.

Icterus, **83**, 717; **84**, 790, 796; **85**, 854, 855, 868; **86**, 5, 37, 44, 53, 64; **87**, 10, 61, 70; **88**, 58; **89**, 4, 35; **90**, 44; **92**, 33; **93**, 24, 35, 44; **94**, 19; **95**, 91 24
—neonatorum, **85**, 868 1
Cholæmia, **85**, 855 1
Rupture, **95**, 38, 88 2

GALL-BLADDER—

Ecchymoses, **95**, 93 1
Gallstones, **83**, 750; **85**, 855; **90**, 27, 60, 64, 68; **87**, 41, 75, 80; **89**, 6, 20; **91**, 42; **92**, 24, 36, 45; **93**, 38, 42, 44; **95**, 57 18
Amyloid (see degeneration) .....
Cyst, **90**, 4 1
Bile duct (obstructive dilatation), **83**, 720; **84**, 790; **86**, 64; **88**, 79; **92**, 24, 36 6
Cystic duct, **84**, 796; **86**, 14; **87**, 88 3
Cholecystitis ch. obliterative, **92**, 24, 36, 45 3
—Perforative, **86**, 64; **90**, 19 2

PERITONEUM—

Ascites, (see circulation, p 90) ..
—chylous, **93**, 737 1
Free fibrous body, **90**, 2 1
Hæmorrhage, **95**, 57 1
Ecchymosis, **94**, 21a 1
Gaseous emphysema, **88**, 29 1
Omentum fat necrosis, **87**, 75 1
Carcinoma (sec.), **85**, 834, 869; **87**, 8; **89**, 67; **91**, 20, 43; **95**, 50, 97 8
Sarcoma (prim.), **89**, 21; **93**, 28 ... 2
—(sec.), **85**, 854; **95**, 51 2

TUBERCULOSIS—

Pleura, **83**, 709, 754; **84**, 782, 784, 798; **85**, 837, 859, 874; **86**, 12, 14, 24, 35, 41, 75; **87**, 20; **89**, 1, 60; **90**, 29, 41, 51, 62; **92**, 34, 50; **94**, 40; **95**, 35, 80, 87, 96 23

Tuberculosis.

Peritonitis acute general, **83**, 772, 780; **84**, 809; **85**, 827, 846, 860, 864; **86**, 18, 22, 64, 66; **87**, 2, 13, 15, 19, 29, 62, 73, 75, 79, 90; **88**, 79, 80; **89**, 53; **90**, 19, 23, 37, 57; **91**, 43; **92**, 21, 35, 39, 66; **94**, 24, 31, 33; **95**, 4, 7, 22, 41, 47, 64, 68, 78, 87, 93, 95, 97 47
Acute perforative peritonitis, **83**, 730, 758; **85**, 843, 853, 861, 878, 887; **86**, 41; **87**, 50, 53, 71; **88**, 20, 39, 72; **89**, 13, 24, 26; **90**, 22, 32, 55, 69; **91**, 40; **92**, 28, 45; **94**, 4, 22; **95**, 64, 69, 87 29
Sub acute, **89**, 21, 86 2
Hæmorrhagic, **93**, 40 1
Acute local purulent, **91**, 20; **93**, 41 2
Tuberc. peritonitis, **83**, 730, 766; **84**, 782, 798; **85**, 825; **86**, 7, 9, 12, 35, 50; **87**, 3, 39, 81; **88**, 1; **89**, 66; **90**, 24, 31; **92**, 34; **95**, 35, 77, 87, 92, 96 23
Chronic adhesive peritonitis, **83**, 720; **84**, 798; **85**, 854, 860, 868, 876, 886; **86**, 22, 52, 59, 64; **87**, 44, 45; **88**, 49, 51, 79; **89**, 1, 22, 50, 53; **90**, 15, 16, 19, 28, 53, 54; **91**, 20; **92**, 48; **93**, 33, 41, 60; **94**, 32; **95**, 12, 25, 37, 42, 50, 68, 75, 91 40
Chronic perihepatitis, **83**, 730, 741. 2
Chronic pelvic peritonitis, **83**, 701; **85**, 825; **86**, 11, 63; **87**, 85; **88**, 51; **92**, 48 7
Chronic perisplenitis, **83**, 748 1
Melanotic pigmentation, **93**, 37 ... 1
Slaty pigmentation, **87**, 40; **90**, 8 2
Hernia strangulated, **86**, 22; **88**, 59; **89**, 18; **92**, 55 4
—inguinal, **86**, 22, 41; **87**, 21; **88**, 58, 68; **89**, 18; **90**, 8, 28 8
—umbilical, **83**, 735; **88**, 89; **95**, 75 3
—diaphragmatic, **85**, 851; **95**, 82. 2
—retro peritoneal, **95**, 90 1
Omental hernia, **88**, 89; **95**, 75 .. 2

Tuberculosis.
—abscess, **90**, 13 1
Mesentery (see also glands mesentric).

PANCREAS.

Laceration, **95**, 87 1
Hæmorrhagic, **93**, 28, 34 2
Abscess, **88**, 79 1
Pancreatitis, (chronic interstitial with cysts), **89**, 69 1

Pancreas.
—hæmorrhagic, **88**, ; **92**, 51..
Fat necroses, **92**, 51 1
Carcinoma, **83**, 737 ; **85**, 823 ; **86**, 27, 66 4
Epithelioma (secondary), **95**, 74... 1
Sarcoma " **95**, 51.... 1
Amyloid, **90**, 29 1

URINARY SYSTEM.

KIDNEY.

Horseshoe, **84**, 804 ; **93** (triangular), 780 2
Moveable, **93**, 65 1
Hypoplasia, **85**, 836 1
Hyperæmia (extreme), **86**, 51, 80 ; **89**, 73 3
Infarcts, **83**, 776 ; **85**, 859 ; **86**, 2, 31, 43 ; **87**, 29, 41, 67 ; **88**, 21 ; **89**, 35 ; **90**, 18, 43 ; **91**, 38 ; **93**, 15, 46 ; **94**, 5, 21 17
Cloudy swelling, **83**, 729, 733, 750, 758; **84**, 790; **85**, 851*a*, 854 (icterus), 887 ; **86**, 8, 18, 30, 31, 55, 57 ; **87**, 13, 15, 36, 58, 68, 73 ; **88**, 30, 31, 32 ; **89**, 7, 14, 33, 65, 71 ; **90**, 16, 30, 55, 64, 69 ; **91**, 35, 38 ; **92**, 21, 28 ; **93**, 38, 41, 54, 59 ; **94**, 9, 34 ; **95**, 41, 46, 47, 50, 53, 72 64
Acute parenchymatous nephritis, **83**, 740 (scarlatina), 779 ; **85**, 856 ; **86**, 74, 84 ; **87**, 6, 23, 25, 58, 85, 87, 88, 90 ; **88**, 7 ; **89**, 8, 19 (glom.), 53, 58, 64 ; **90**, 2, 36, 44 ; **91**, 20, 32 ; **93**, 30*a* (glom.), 44, 48, 50, 52, 61 ("glomerulo.") ; **94**, 7, 10, 15, 43 ; **95**, 5, 15, 24, 25, 30, 43, 49, 62, 65, 75 44

Kidney.
Acute hæmorrhagic nephritis, **88**, 63 ; **89**, 57 ; **94**, 4 ....
Chronic (mixed) parenchymatous nephritis (large white kidney), **83**, 716 (chylous ascites) ; **84**, 796, 813 ; **85**, 826, 876 ; **86**, 34, 37, 43 ; **87**, 23, 25, 77 ; **88**, 26, 42, 51, 78 ; **90**, 54, 66 ; **93**, 26, 27, 35, 45, 57, 62, 63, ; **94**, 11, 12 ; **95**, 35, 48, 91 28
Anæmic fatty, **83**, 748 ; **85**, 829 ; **88**, 33, 78 ; **93**, 12, 26 ; **94**, 30, 43. 8
Amyloid (see amyloid degen).
Nephritis, chronic interstitial, small granular kidney, **83**, 701, 703, 722, 723, 727, 732, 734, 743, 753, 763, 767, 769, 776 ; **84**, 785, 787, 797, 802 ; **85**, 821, 828, 830, 833, 841, 844*a*, 846, 885, 847, 852, 860, (sl.), 864, 876 (large), 836, 851*a* ; **86**, 7, 27, 34, 47, 49, 62, 63 ; **87**, 6, 9, 23, 25, 35, 40, 49, 63, 67, 74, 88 ; **88**, 8, 10, 23, 40, 43, 51, 57 58, 71 ; **89**, 1, 5, 6, 7, 10, 16 (ext. cirrh.), 20 (cirrh.), 47, 50, 60, 63, 72, 74, 75 ; **90**, 2, 10 (sl.), 35, 50 ; **91**, 20, 29, 37, 47 ; **92**, 20, 39, 54, 58, 60 ; **93**, 15, 22, 27, 28, 34, 35,

Kidney.

37, 40, 49, 55 (sen., 62, 65; **94**, 2, 14, 18, 19, 27, 31, 32, 42, 45; **95**, 1, 7, 9, 20, 26, 27, 31, 35, 39, 43, 44, 48, 55, 59, 68*a*, 63, 61, 70, 82, 83, 37, 76, 32, 66, 73, 96 133
Hogback, **87**, 45; **90**, 6, 21, 59; **92**, 61; **93**, 21; **94**, 7; **95**, 16 .. 8
Cyanotic indurations, **83**, 708, 771, 778, 779; **84**, 810; **85**, 815; **86**, 1, 5, 51; **87**, 44, 84, 87; **88**, 68; **89**, 43, 66, 70; **90**, 1, 3, 25, 28, 60, 65; **95**, 3, 79 24
Miliary tuberculosis, **83**, 713, 774; **84**, 782, 783; **85**, 825, 870, 879, 882; **86**, 12, 35, 38, 41, 73; **87**, 3, 5, 69, 79, 81; **88**, 1, 5, 27; **90**, 29; **92**, 37, 43; **93**, 23, 43; **94**, 34; **95**, 28, 49, 54, 87 29
Compensating hypertrophy, **85**, 836; **91**, 29, ... 2
Leuchæmia, **83**, 704 1
Fibroma, **87**, 6 1
Primary sarcoma, **83** 718 1
Secondary " **86**, 48 1
Primary cancer, **85**, 869; **90**, 51 .. 2
Secondary " **86**, 27; **89**, 56 ... 2
Cysts, **86**, 63, 81; **92**, 20 3
Rupture, **83**, 757; **85**, 871; **95**, 38 3
Urate deposits, **85**, 868; **89**, 47 ... 2
Renal calculus, **83**, 760; **84**, 804; **86**, 11, 17; **87**, 28; **90**, 33, 53; **93**, 25 (oxalate), 64 9
Adrenal rests (see adrenal, p. 86) ..
Hyaline degeneration, **90**, 17 1
Purulent perinephritis, **86**, 17 1
Gangrenous " **90**, 51 ... 1
Embolic nephritis, **83**, 708, 711; **89**, 2; **90**, 15; **91**, 42; **92**, 51; **93**, 25 7
Hydronephrosis, **83**, 719; **84**, 804, **85**, 817, 854; **87**, 28, 32; **88**, 7; **90**, 2, 20, 31, 67; **91**, 29; **92**, 11, 25, 62, 65; **95**, 34, 74 18
Acute bacterial papillary nephritis, **95**, 17, 92 2

Kidney.

Acute hæmorrhagic pyelitis, **95**, 84 1
Pyonephrosis, **83**, 760; **84**, 804; **86**, 9, 11, 17, 85; **87**, 10, 32, 54; **88**, 7, 37; **90**, 2, 5, 9, 33, 42, 45; **92**, 38, 44, 51; **93**, 18, 25, 40; **95**, 74, 94 25
Tuberculous pyelitis, **83**, 754; **85**, 859; **86**, 28, 70; **87**, 5, 8; **88**, 36; **89**, 11; **95**, 92 8

URETER.

Obliteration, **87**, 10 1
Dilatation, **88**, 7; **92**, 51 2
Double, **95**, 24 1
Tuberculosis, **95**, 92 1
Fistula, **87**, 54 1

BLADDER.

Diverticulum, **83**, 783; **86**, 19 2
Dilatation, **85**, 859 1
Dilatation hypertrophy, **87**, 32, 70; **91**, 42 3
Hypertrophy, **92**, 38, 44 2
Fistula recto-vesical, **89**, 11; **95**, 12 2
—recto-vesico-vaginal, **95**, 31 1
Cystitis (chronic), **83**, 705; **86**, 9, 17, 58, 70; **88**, 37; **90**, 5, 42; **92**, 44; **93**, 25, 41 11
—acute hæmorrhagic, **86**, 57, 63; **89**, 2; **93**, 40; **95**, 2, 6 6
—phlegmonous, **95**, 52 1
—diphtheritic, **83**, 756; **90**, 6 2
—tuberculous, **83**, 754; **85**, 859; **86**, 28; **87**, 81; **90**, 40 5
Papilloma, **87**, 49 1
Cyst (submucous), **87**, 82 1
Epithelioma (primary), **95**, 74 1
Primary cancer (colloid), **90**, 20 ... 1
Secondary carcinoma, **83**, 719; **93**, 11; **95**, 31 4
Vesical calculus, **86**, 17; **88**, 58; **93**, 18; **95**, 74 4

URETHRA.

Fistula, **83**, 754; **86**, 70; **90**, 15 .. 3
—fistula tuberculous, **87**, 5, 81; **90**, 6 3

Urethra.
—laceration, **85**, 845; **86**, 51, 58; **89**, 73 4
—stricture, **85**, 817, 845, 859; **86**, 51; **89**, 73; **90**, 5, 15, 45, 67, 92; **91**, 42; **92**, 44 12

Urethra.
Peri urethral abscess, **85**, 817; **86**, 52, 58 3
Gonorrhœa, **90**, 17, 64 2
Epithelioma, **90**, 31 1

GENITAL SYSTEM—MALE.

PENIS—
Scar of glans, **86**, 24; **88**, 68; **95**, 56, 74 4
Condylomata, **87**, 36 1
Balanitis, **95**, 5, 68*a* 2
Paraphimosis, **95**, 68*a* 1
Epithelioma, **83**, 762; **95**, 68*a* 2

PROSTATE—
Hypertrophy, **83**, 723; **86**, 5, 7, 9, 17, 81, 85; **87**, 32, 70; **88**, 7, 37; **90**, 67; **92**, 38; **93**, 18; **95**, 11, 12, 20, 26, 39, 86, 96 21
Necrosis, **92**, 38; **84**, 817; **86**, 85. 3
Purulent prostatitis, **90**, 1, 2, 5 3
Tuberculosis, **86**, 70; **92**, 29 2
Copora amylacea, **87**, 89; **89**, 35; **95**, 91, 96 4
Primary carcinoma, **93**, 11 1

Prostate.
Vesiculitis chronic purulent, **95**, 12 1
—tuberculous, **86**, 28 1
Atrophic, **90**, 9 1

TESTICLE—
Hydrocele, **87**, 21; **90**, 28; **95**, 18, 76 4
Cyst of tunica vaginalis, **94**, 8 1
Cyst of epididymis, **90**, 40 1
Cryptorchidismus, **95**, 68 1
Orchitis tuberculous, **85**, 822; **86**, 70; **87**, 5; **92**, 29; **95**, 92 5
Orchitis gummatous, **92**, 32, 40; **95**, 71 3
—fibrous, **85**, 876; **92**, 44; **95**, 86. 3
—purulent, **85**, 876 1
Castration, **90**, 9; **95**, 12 2

GENITAL SYSTEM—FEMALE.

VULVA—
Abscess, **87**, 38 1
Œdema, **89**, 3 1
Noma, **84**, 784 1
Condylomata, **94**, 21*a* 1
Elephantiasis of labia, **84**, 781 1

VAGINA—
Fistula, recto-vesico-vaginal, **84**, 781 1
—vaginitis tuberculous, **83**, 719 1
—diphtheritic, **83**, 769; **87**, 54 2
—phlegmonous, **94**, 10; **95**, 75 2
Lacerations parturition, **95**, 75 1

UTERUS—

Uterus septus, **85**, 836, 850..... 2
Chronic endometritis, **83**, 778; **87**, 41, 75; **88**, 26, 84; **94**, 21a, 24; **95**, 5..... 8
Diphtheritic, **86**, 18, 30; **87**, 2, 13, 15, 19; **93**, 54; **94**, 10; **95**, 75... 9
Putrid endometritis, **86**, 30..... 1
Tuberculous endometritis, **94**, 20. 1
Purulent peri and parametritis, **87**, 13, 15; **89**, 7, 13; **90**, 37.... 5
Pelvic abscess, **95**, 75..... 1
Chronic adhesive perimetritis, **86**, 30; **87**, 45 52, 60; **88**, 19; **90**, 37; **93**, 39..... 8
Uterus and pelvic thrombo phlebitis, **86**, 30; **90**, 36; **92**, 43, 54. 4
Fibro myoma, **83**, 702, 712, 739; **85**, 836, 860; **86**, 43; **87**, 67; **88**, 40; **89**, 57; **90**, 14; **93**, 37; **94**, 32; **95**, 17, 45, 97..... 15
Polypi, **85**, 864; **88**, 49; **89**, 1; **92**, 39; **95**, 5..... 5
Carcinoma (primary), **83**, 719; **95**, 31..... 2
—(secondary), **95**, 97..... 1
Sarcoma, **90**, 57..... 1
Pregnancy, **83**, 727; **88**, 17, 20; **89**, 31; **94**, 20; **95**, 4, 36.. 7
—ruptured tubal, **95**, 4..... 1
Puerperal state, **83**, 727; **86**, 18, 30, 57; **87**, 2, 13, 15, 19, 41, 88; **89**, 7; **90**, 36; **92**, 42. 51, 59; **95**, 5, 75..... 17
Abortion, **89**, 64..... 1
—criminal, **86**, 57..... 1
Puerperal eclampsia, **89**, 31..... 1
Subinvolution, **86**, 18, 30; **87**, 2, 41, 52; **88**, 83; **90**, 36; **92**, 51;

Uterus.

93, 54; **95**, 19, 53, 75..... 11
Menstruation, **83**, 706; **95**, 95.... 2

FŒTUS—

Hydramnios, **87**, 18..... 1

FALLOPIAN TUBES.

Hydrosalpynx, **83**, 741; **87**, 45; **89**, 14, 16, 69 5
Pyosalpynx, **83**, 767; **85**, 827, 846; **87**, 60; **88**, 51; **90**, 37; **93**, 41; **94**, 24..... 8
Gangrenous cyst, **90**, 37 1
Calcification of fimbriæ, **83**, 778 .. 1
Tuberculous salpingitis, **85**, 825; **86**, 35; **92**, 34; **94**, 64 4

OVARIES—

Abscess, **85**, 846..... 1
Cystic, **86**, 71; **94**, 21*a*; **95**, 97. 3
Papillary cystoma, **83**, 745; **95**, 78 2
Cystoma, **87**, 3; **88**, 40; **89**, 62; **90**, 37, 51; **91**, 34; **95**, 22 7
Dermoid, **94**, 24..... 1
Fibro-cystic sarcoma, **85**, 854 1
Chronic fibroid ovaritis, **87**, 19; **93**, 16 2
Calcareous degeneration, **93**, 34.. 1
Broad ligament cyst, **83**, 767; **87**, 13 2
Parovarian cyst, **88**, 831; **89**, 14; **95**, 54..... 3
Retro-peritoneal hæmatocele, **95**, 78 1

MAMMA—

Purulent mastitis, **89**, 64..... 1
Primary cancer, **87**, 1; **91**, 40*a* .. 2

NERVOUS SYSTEM.

DURA—

Pachymeningitis (acute), **91**, 35... 1
—subacute, **89**, 54 1
—chronic adhesive, **83**, 773; **87**, 21; **90**, 56; **93**, 14..... 4
—hæmorrhagic, **88**, 6; **95**, 56, 68*a*. 3
—ossifying, **89**, 6, 68; **95**, 96..... 3
—purulent, **87**, 27; **89**, 14; **94**, 30. 3
Hæmorrhage longitudinal sinus (new born), **88**, 12..... 1
Extra meningeal hæmorrhage, **85**, 872; **86**, 65; **87**, 65..... 3
Inter meningeal hæmorrhage, **83**, 703, 756, 764; **85**, 844, 877; **86**, 12, 14, 19; **87**, 65, 89; **93**, 40; **94**, 2; **95**, 59..... 13

LATERAL SINUS—

Thrombo phlebitis, **88**, 66; **95**, 78*a* 2
Longitudinal sinus, **95**, 77..... 1
Hyperæmia, **86**, 3, 40; **95**, 62..... 3

PIA—

Œdema, **83**, 723, 767; **85**, 883; **86**, 3, 40; **89**, 5; **90**, 15; **93**, 36, 69.. 9
Melanosis, **83**, 708 1
Chronic leptomeningitis, **86**, 80; **87**, 21; **94**, 2; **95**, 69..... 4
Fibrous nodules in pia, **95**, 69..... 1
Acute leptomeningitis, **83**, 708; **85**, 818, 885; **86**, 6, 80; **89**, 54; **91**, 35, 48..... 8
—purulent, **86**, 23; **90**, 26, 88; **91**, 64; **92**, 26; **93**, 64; **94**, 30; **95**, 10..... 8
Milky thickening, **85**, 874; **86**, 3; **90**, 56, 59; **95**, 15, 16, 49, 80, 81.. 19
Meningitis acute tuberculous, **83**, 746; **84**, 782, 792; **86**, 12, 34; **87**, 3, 5, 81; **88**, 1, 17, 35; **90**, 9, 38; **91**, 34; **92**, 37; **93**, 19, 23, 36, 43, 45; **94**, 13, 20, 28; **95**, 6, 28, 29, 40, 54, 77, 87, 92 31
Acute cerebro spinal, **86**, 33, 62; **91**, 39..... 3

BRAIN—

Acute internal hydrocephalus, **84**, 782; **85**, 839; **87**, 1; **86**, 29..... 4
Rupture of abscess into, **93**, 64... 1
Obliteration of ventricles, **89**, 23.. 1
Granular ependymitis, **85**, 835; **86**, 34; **88**, 9; **95**, 54..... 4
Atrophy of convolutions, **86**, 82; **87**, 90; **90**, 39; **94**, 19..... 4
Hæmorrhage, **83**, 703, 708, 727, 728, 752; **84**, 800; **85**, 836; **86**, 47, 54; **87**, 22; **88**, 2, 16, 25, 71; **89**, 74; **90**, 10, 39, 50, 66; **91**, 29; **92**, 20; **93**, 40; **94**, 8, 14; **95**, 56, 48..... 26
Rupture cerebral aneurysms, **90**, 10; **95**, 59..... 2
Multiple ecchymoses, **90**, 7, 65.... 2
Septic " **88**, 66..... 1
Embolism. **85**, 852; **88**, 21; **93**, 46..... 3
Thrombosis, **83**, 774; **86**, 43; **89**, 1; **95**, 9, 14, 86..... 6
Softening, **83**, 722, 752; **84**, 787; **85**, 833, 842; **86**, 43, 74, 78; **87**, 12; **88**, 3, 9; **89**, 1; **93**, 12, 22, 47; **94**, 2; **95**, 9, 49, 56, 86, 87..... 22
Sclerosis, **90**, 65; **95**, 14, 15, 16.... 4
Meningo encephalitis, **88**, 66..... 1
Idiocy, **90**, 63 1
Mania (no orngànic disease), **88**, 33; **93**, 53 2
Epileptic insanity, **90**, 56..... 1
Jacksonian epilepsy, **93**, 64..... 1
Tubercle (solitary), **87**, 3; **90**, 9; **91**, 34; **93**, 40, 43; **95**, 29..... 6
Atheroma vessels, **84**, 787; **95**, 59 2
Gumma, **88**, 3..... 1
Syphilitic endarteritis, **85**, 835; **95**, 9, 14, 86..... 4
Brain abscess, **86**, 68; **87**, 27; **88**, 6; **89**, 40; **91**, 44; **92**, 23; **93**, 64; **94**, 13..... 8
Cystic atrophy corpora striata, **87**, 14; **90**. 8, 66; **94**, 2, 19..... 5
—cortex, **93**, 33, 64; **95**, 37..... 3

Brain.

Calcareous nodules, **86**, 78; **88**, 5. 2
Bullet wound, **86**, 14; **90**, 26..... 2
Laceration, **87**, 65, 89..... 2
Concussion ecchymoses, **83**, 752, 764; **95**, 59..... 3
Trephining (Jacksonian epilepsy), **93**, 64..... 1
Glioma, **90**, 66; **92**, 49; **93**, 17... 3
Glio-sarcoma, **83**, 720; **86**, 29; **87**, 23..... 3
Sarcoma, **89**, 25; **90**, 34; **91**, 45.. 3

CEREBELLUM—

Abscess, **85**, 835..... 1
Solitary tubercles.....

SPINAL CORD—

Dura.....
Gumma chronic meningitis, **92**, 32, 43..... 2
Tuberculous abscess (caries), **95**, 77..... 1

PIA—

Acute cerebro spinal meningitis, **86**, 33, 62; **91**, 35..... 3
Meningitis tuberculous, **92**, 43.... 1
Acute ascending paralysis, **91**, 36. 1
Chronic ascending (acute myelitis), **83**, 742; **90**, 17; **95**, 4*a*..... 3
Paraplegia compression, **85**, 830; **90**, 50; **95**, 77..... 3
Descending degeneration, **88**, 3, 5. 2
Ascending " **86**, 71, 78; **95**, 77..... 3
Gumma, **92**, 32; **93**, 20..... 2

Pia.

Posterior lateral sclerosis, **89**, 12. 1
Tabes, **89**, 20..... 1
Insular sclerosis, **95**, 17..... 1

NERVES—

Acute peripheral neuritis, **84**, 806; **86**, 69; **87**, 7..... 3
Degenerative neuritis (trifacial), **85**, 883..... 1
Cœliac ganglia (grey degeneration), **89**, 60..... 1
Fibrosis, **89**, 63..... 1

EYE—

Optic neuritis, **87**, 3; **89**, 54; **90**, 34..... 3
—atrophy, **86**, 29; **90**, 34..... 2
Retinitis hæmorrhagic, **84**, 801; **90**, 39..... 2
—albuminuric, **84**, 813; **87**, 40; **89**, 74..... 3

EAR—

Chronic purulent otitis media, **86**, 36; **87**, 27, 71, 88; **88**, 1; **89**, 53; **91**, 44; **92**, 56; **95**, 10, 78*a*..... 10
Purulent mastoiditis, **95**, 10..... 1
Hæmorrhage into tympanum, **95**, 55..... 1
Bullet wound, **88**, 64..... 1
Vagus, hæmorrhage of sheath, **90**, 11..... 1
—suppuration of sheath, **90**, 24... 1
—pressure aneurysm, **86**, 83; **87**, 35..... 2

LOCOMOTOR SYSTEM.

PONES.

Purulent ostitis (frontal), **83**, 780; **88**, 6; **89**, 40; **90**, 28; **93**, 56. frontal, **94**, 30..... 6
—periostitis, **83**, 773; **94**, 30 (skull) 2
Suppuration anterior (maxilla), **90**, 26..... 1
Sclerosing osteitis (syphilitic), **83**, 773; **90**, 54..... 2
Necrosing osteitis, **91**, 37; **93**, 64. 2
Secondary carcinoma (vertebræ), **87**, 8; **91**, 40*a* (vertebræ), **95**, 4..... 3
Sarcoma ossifying, **85**, 840..... 1
Tibia, **88**, 43..... 1
Frontal, **95**, 59..... 1
Tuberculous caries (vertebræ), **83**, 714; **85**, 820, 882; **87**, 8; **92**, 37, 43; **93**, 45; **95**, 49, 77..... 9
—ribs, **94**, 17; **95**, 49..... 2
—kyphosis, **95**, 77..... 1

FRACTURES—

Face, **95**, 40, 54..... 2
Vertebræ, **86**, 87; **87**, 48, 56; **95**, 38..... 4

Fractures.

Skull, **83**, 703, 721, 756; **85**, 844, 872; **86**, 19, 65; **87**, 27, 32, 65, 89; **88**, 64; **89**, 32; **90**, 26; **91**, 46; **92**, 23; **95**, 36, 49, 63 19
Ribs, **83**, 757; **85**, 871; **86**, 58; **87**, 21; **93**, 16; **95**, 36, 38, 40, 55, 57, 68*a*, 82, 84 13
Clavicle, **87**, 21; **95**, 36, 68 3
Arm, **85**, 871; **87**, 4; **89**, 32; **95**, 84 4
Leg, **83**, 780; **87**, 4, 49; **89**, 38, 51, 58; **91**, 46, 47; **94**, 18; **95**, 37, 38, 60, 76, 84 14
Pelvis, **89**, 51; **91**, 46 2
Sternum, **87**, 21; **95**, 68*a* 2
Erosion of sternum from pressure of aneurysm, **86**, 83; **87**, 79; **88**, 23; **94**, 32 4
—vertebræ, **94**, 32 1
Exostosis, **93**, 26 1
Hyperostosis, **93**, 26 1
Hypertrophic osteitis, **93**, 16 (frontal) 1
Osteophytes cranium, **94**, 4 1
Fragilitas ossium, **89**, 877 1
Rachitis, **85**, 839; **87**, 17, 54; **89**, 46; **95**, 19 5

Fractures.

Flat pelvis, **87**, 54 1
Ribs (bifid), **85**, 838; **95**, 94 2

JOINTS—

Acute synovitis, **90**, 18 1
Purulent arthritis, **83**, 717, 777; **84**, 781; **85**, 886; **86**, 15; **87**, 2, 74; **88**, 21, 55; **92**, 50 10
—perichondritis, **87**, 57 (typhoid) . 1
Gout, **89**, 47 1
Anchylosis, **85**, 852 (knee), **87**, 3 (ankle), **88**, 14 (hip), **95**, 92 (knees and hip) 5
Dislocation, **86**, 19, 87 (vertebræ), (sterno clav); **87**, 56 (vertebræ). 4
Tuberculous arthritis, **87**, 79; **95**, 34, 35; **93**, 45 4

MUSCLE—

Trichinosis, **89**, 5, 29 2
Hyaline degeneration, **89**, 49 1
Abscess pectoral, **89**, 17 1
—psoas, **85**, 822; **92**, 37; **95**, 94 .. 3
Atrophy, **92**, 50 1
Myositis acute parenchymatous, **94**, 30 1

SKIN AND SUBCUTANEOUS TISSUE.

Purpura, **84**, 811; **86**, 54, 61; **88**, 63; **86**, 49; **94**, 4; **95**, 19 7
Sudamina, **88**, 79 1
Erythema nodosum, **89**, 69 1
Burns, **95**, 90 1
Bedsores, **86**, 36; **87**, 5; **88**, 43; **89**, 3, 4; **90**, 6, 29; **93**, 12, 33*a*; **94**, 26; **95**, 25, 77, 94, 96 14
Bronzing, **85**, 863, 865; **89**, 61; **93**, 42 4
Leucoderma, **86**, 41; **93**, 42 2
Gangrene, **88**, 37, 41; **90**, 18 3
Simple ulcer, **86**, 27; **87**, 42; **88**, 21; **90**, 14 4
Syphilitic ulcer, **89**, 35; **91**, 42 ... 2
Tuberculous (lupus), **88**, 28 1
Pustular eczema, **85**, 851*a*, **89**, 3; **95**, 5 3
Erysipelas, **86**, 15, 45; **87**, 36; **92**, 40; **94**, 30, 43; **95**, 46 7
Phlegmon, **88**, 21; **90**, 16, 24 3
Sinus, **85**, 840; **92**, 3 2
Carbuncle (diabetes), **87**, 86; **92**, 53 2
Farcy, **85**, 848 1
Pemphigus, **84**, 789 1
Psoriasis, **84**, 781 1
Elephantiasis, **84**, 781 1
Sarcoma, **90**, 60; **89**, 48; **95**, 51 . 3
Sebaceous cyst, **92**, 29 1
Fat (ochre yellow degeneration), **87**, 38; **95**, 21, 44, 62 4
Int rstitial emphysema, **90**, 24 ... 1

..... 1
4 2

. 1
17, 777;
5; **87**,
..... 10
phoid) . 1
..... 1
e), **87**,
95, 92
..... 5
tebræ),
tebræ). 4
9; **95**,
..... 4

..... 2
49..... 1
..... 1
5, 94.. 3
..... 1
atous,
..... 1

; **92**,
..... 7
4..... 3
..... 2
; **92**,
..... 2
..... 1
..... 1
..... 1
..... 1
5, 51. 3
..... 1
tion),
..... 4
24... 1